



Assessing the Ankle Joint Line Level Before and After Total Ankle Arthroplasty With the “Joint Line Height Ratio”

Thos Harnroongroj, MD^{1,2} , Amelia Hummel, BA¹, Scott J. Ellis, MD¹ , Carolyn M. Sofka, MD³, Kristin C. Caolo, BA¹, Jonathan T. Deland, MD¹, and Constantine A. Demetracopoulos, MD¹

Abstract

Background: Restoring the joint line is an important principle in total knee arthroplasty. However, the effect of joint line level on patient outcomes after total ankle arthroplasty (TAA) remains unclear, as there is no established method for measuring ankle joint level in TAA. The objective of this study was to develop a reliable radiographic ankle joint line measurement method and to compare ankle joint line level measured pre-TAA, post-TAA, and in nonarthritic ankles.

Methods: A total of 112 radiographic sets were analyzed. Each set included weightbearing anteroposterior radiographs of the operative ankle taken preoperatively, 1-year postoperatively, and of the contralateral ankle. Measurements of vertical intermalleolar distance (VIMD) and vertical joint line distance (VJLD) at pre-TAA, post-TAA, and of the contralateral ankle were recorded by 2 authors on 2 separate occasions. The ratio of VJLD to VIMD was defined as the joint line height ratio (JLHR). Reliability of measurements and correlation between VIMD and VJLD were assessed. Pre-TAA, nonarthritic contralateral ankle, and post-TAA JLHR were compared and considered significantly different if $P < .05$.

Results: The inter- and intrarater reliability of radiographic measurements was excellent ($r > 0.9$). There were strong positive correlations of VIMD and VJLD, $r = 0.809$ (pre-TAA)/ 0.756 (post-TAA), $P < .001$. Mean (SD) pre-TAA, nonarthritic contralateral ankle, and post-TAA JLHRs were 1.54 (0.31), 1.39 (0.26), and 1.62 (0.49), respectively. Pre- and post-TAA JLHRs were significantly higher compared to the nonarthritic contralateral ankle ($P < .05$). JLHR was not significantly different between pre- and post-TAA ($P = .15$).

Conclusion: The JLHR was reliable and could be a clinically applicable method for assessing ankle joint line level in patients undergoing TAA. End-stage ankle arthritis demonstrated elevated joint line level compared with nonarthritic ankles, and the joint line level post-TAA remained elevated compared with nonarthritic ankles. Further studies are needed to understand the effect of joint line elevation on clinical outcomes after TAA.

Level of Evidence: Level III, retrospective comparative study.

Keywords: joint line height ratio, vertical intermalleolar distance, vertical joint line distance, pre-TAA, post-TAA, Nonarthritic contralateral ankle

Introduction

Total ankle arthroplasty (TAA) is a well-accepted treatment option for patients with end-stage ankle arthritis.^{8,9,11}

Despite potential concerns about long-term survivorship, the current literature supports satisfactory outcomes,^{11,17,19} and there is evidence that the latest TAA designs result in improved patient-reported outcomes when compared to ankle arthrodesis.^{1,2} TAA has also been shown to successfully alleviate pain and preserve range of motion at the ankle joint.

¹ Foot and Ankle Service, Department of Orthopaedic Surgery, Hospital for Special Surgery, New York, NY, USA

² Department of Orthopaedics and Rehabilitation, Faculty of Medicine, Siriraj Hospital, Mahidol University, Bangkok, Thailand

³ Department of Radiology and Imaging, Hospital for Special Surgery, New York, NY, USA

Corresponding Author:

Thos Harnroongroj, MD, Department of Orthopaedics and Rehabilitation, Faculty of Medicine, Siriraj Hospital, Mahidol University, 2 Wanglang Road, Bangkok 10700, Thailand.

Email: ultradeutsch@gmail.com



The restoration of the native joint line level is an important principle in knee arthroplasty.^{5,13} Many studies show that better clinical outcomes are correlated with restoring the native joint line level following total knee arthroplasty (TKA).^{6,7,13,23} Joint line lowering after TKA is associated with tightening of midrange knee motion and is a potential risk for patellar subluxation, which can lead to retropatellar pain.^{7,15} On the contrary, joint line elevation after TKA causes decreased range of motion, joint stiffness, pseudo-patella baja, and midflexion instability.^{4,22} The maximum amount of joint line changing in TKA associated with poor clinical outcomes is still controversial, because values have been reported as ranging from 4 to 6 mm.^{10,25,26}

Despite the satisfactory outcomes after TAA in end-stage ankle arthritis, there is a lack of evidence describing whether TAA is able to restore the joint line back to its native level as well as if changes in the joint line level after TAA affect clinical outcomes. One major limitation in the existing literature is the absence of an available method for the radiographic measurement of the ankle joint line level before and after TAA. Therefore, establishing a reliable and reproducible ankle joint line level measurement method is an important prerequisite to conducting further studies that examine the relationship between joint line level and clinical outcomes.

The radiographic measurement methods of joint line level in TKA^{12,14,20,21} identify constant structures that remain at a static level before and after surgery. The value obtained from this method can be reported as an absolute number or a ratio.^{12,14,20} This measurement method validated in TKA can be applied to the ankle joint using ankle-specific anatomic landmarks. The tips of the medial and lateral malleolus (in the absence of concomitant medial malleolar or fibular osteotomy) are not involved in TAA and therefore remain constant before and after surgery. As a result, they can be used to create a method for radiographic measurement of the joint line level that can be used before and after TAA.

End-stage ankle arthritis usually causes the destruction of cartilage and subchondral bone in both the tibia and talus.^{18,24} Because of the difference in bone strength between the tibia and the talus,^{3,16} the talar dome is more likely to erode the distal tibial subchondral bone over time, resulting in ankle joint line elevation. TAA techniques reference the joint line of the arthritic ankle when determining the initial tibial and talar cuts. Therefore, the ankle joint line after TAA may remain unchanged but is still elevated when compared to the native or nonarthritic ankle due to bone erosion.

The objective of this study was to propose a reliable radiographic method to measure the ankle joint line level that can be applied both before and after TAA. To do this, we compared the ankle joint line level before and after TAA, as well as the pre-TAA side to the nonarthritic contralateral ankle. We hypothesized that the arthritic ankle (pre-TAA) would have an elevated joint line level compared to the

nonarthritic contralateral side (native ankle) and that there would be no difference in the joint line level before and after TAA.

Methods

This study was approved by the Institutional Review Board at the investigators' institution. We included anteroposterior (AP) ankle weightbearing radiographs of end-stage ankle arthritis patients without contralateral ankle arthritis undergoing primary TAA between January 2014 and August 2017. All TAAs were performed by a single surgeon.

The primary inclusion criteria consisted of age at the time of surgery between 40 and 70 years; body mass index between 20 and 40; follow-up radiographs at least 1 year following TAA. The exclusion criteria consisted of patients who had contralateral ankle arthritis or other ankle diseases that would preclude comparison between ankles; concomitant fibular or medial malleolar osteotomy that would distort the bony landmarks used for the measurements; revision TAA; radiographic component loosening during follow-up that could lead to a change in joint line position.

From a total of 125 patients' radiographs, 13 were excluded—7 because of contralateral ankle arthritis and 6 because of adjunctive fibular or medial malleolar osteotomy—leaving 112 patients for the study.

All weightbearing AP ankle radiographs were taken with the same radiographic technique using PhilipsDigitalDiagnost (Philips Research, Eindhoven, the Netherlands). The patients were placed in standing position, and the film focus distance was 122 cm. The beam projection was directly perpendicular to the leg. The radiation source setting was 60 kV and 3.2 mA. All radiographs were evaluated to ensure the images were obtained using the standardized technique, with emphasis on performing the measurements on a true AP line of the ankle.

There were 61 male (55.5%) and 51 female (45.5%) patients. The mean (standard deviation) age and body mass index were, respectively, 62.8 (6.9) years and 28.3 (4.7). The etiologies of end-stage ankle arthritis included 81 post-traumatic (72.3%) and 31 primary (27.7%). The TAA implants used (number, percentage of total implants used) included the Infinity (51, 45.5%) and INBONE II (19, 17.0%) (Wright Medical, Memphis, TN), Cadence (16, 14.3%), Salto Talaris (15, 13.4%) (Integra LifeSciences, Plainsboro, NJ) and Vantage (11, 9.8%) (Exactech, Gainesville, FL).

Joint Line Measurement Methodology

The measurement methodology for the ankle joint line level using constant pre- and postoperative landmarks was modeled off that previously described in TKA.^{12,14,20,21} We used a ratio instead of an absolute value because standardized markers were not included in the radiographs, preventing us from precisely accounting for magnification. The sex and

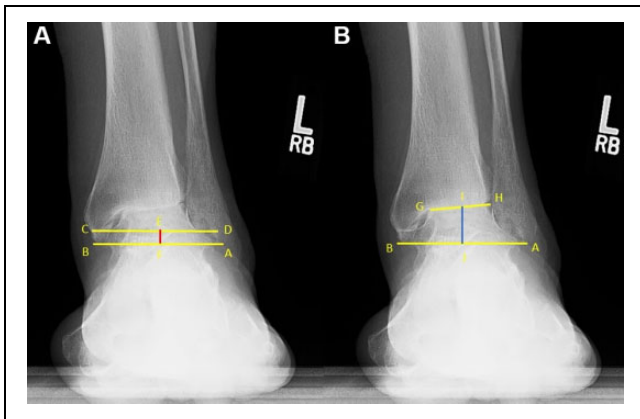


Figure 1. (A) The joint line height ratio pre-TAA. EF was vertical intermalleolar distance (red line). (B) IJ was vertical joint line distance (blue line). The ratio was calculated as IJ/EF . The measurement for the nonarthritic contralateral ankle radiograph was performed in the same fashion.

the size of the ankle could also be potential confounders when assessing absolute values.^{12,14,20}

All measurements were completed using a picture archiving and communication system (PACS; Philips Medical Systems, Best, Netherlands). For preoperative TAA and nonarthritic contralateral AP ankle weightbearing radiographs, the tip of the lateral malleolus and posterior colliculus of medial malleolus were identified as A and C, respectively (Figure 1A). Two lines, originating from A and C, were drawn parallel to the ground. The resulting lines were AB and CD (Figure 1A). Then, a line (EF) connecting AB and CD was drawn perpendicular to AB and CD (Figure 1A). The EF line was measured as the vertical intermalleolar distance (Figure 1A).

Next, the medial-most and lateral-most points of the talar dome were identified as G and H, and the line GH between the 2 points was drawn and measured for distance. The midpoint of the GH line was marked as I. The point I was considered the center of the ankle at the joint line. Then, line IJ was drawn perpendicular to the ground and ended at the point connected to line AB. The length of the IJ line was measured as the vertical joint line distance (Figure 1B). The ratio between the vertical joint line distance (IJ) and the vertical intermalleolar distance (EF) was calculated as the “joint line height ratio” pre-TAA. A joint line height ratio of the nonarthritic contralateral ankle was calculated using the same set of lines and landmarks previously described.

The tip of the posterior colliculus was utilized as a landmark instead of the anterior colliculus because osteophytes at the tip of anterior colliculus were a common finding in patients with end-stage ankle arthritis radiographs, therefore making this landmark less reliable.

For postoperative TAA radiograph, the joint line height ratio post-TAA was measured using the same process with the exception of identifying the joint line center of the ankle. Points G and H were marked at the uppermost medial and

lateral points of the talar component. The line GH was drawn and the midpoint of the GH distance was identified as I. The point I was determined as the center of the joint line post-TAA (Figure 2).

Measurements for joint line height ratio were done for pre-TAA and the nonarthritic contralateral side using the preoperative TAA radiograph and for post-TAA using the follow-up radiograph at 1 year after the operation. All measurements were performed twice with 4 weeks in between each measure by 1 fellowship-trained foot and ankle orthopedic surgeon and 1 research assistant who was trained in this measurement method. The comparisons between joint line height ratio of pre-TAA, nonarthritic contralateral ankle, and post-TAA, which included subgroup analysis on the TAA implants, were then analyzed.

Statistical Analysis

Data analysis was performed using IBM SPSS Statistics for Windows 21.0 (IBM Corp, Armonk, NY). The categorical data was presented as numbers, percentages, and ratios. A Kolmogorov-Smirnov test was used to test the normality of the numerical variables. The numerical data were presented as the mean (SD) for normally distributed data and the median (interquartile range) for non-normally distributed data. The intra- and interrater reliabilities of the measurements were assessed using intraclass correlation coefficients and 95% confidence intervals. The linear regression model was used to assess the degree of correlation between the vertical intermalleolar distance and vertical joint line distance. The joint line height ratio for the pre-TAA, nonarthritic contralateral ankle, and post-TAA, which included subgroup analysis on each utilized TAA implant, were compared using paired *t* tests and a 1-way analysis of variance for normally distributed variables; as well as a Wilcoxon signed rank test for non-normally distributed data. A difference of $P < .05$ was considered statistically significant.

Results

The intra- and inter-rater reliability for all measurements was excellent (Table 1). Because of the reliability within and between raters across all parameters, the measurement values of the first rater were used for further analysis. According to the Pearson correlation test, there were strong positive correlations of vertical intermalleolar distance and vertical joint line distance, with *r*'s of 0.809 and 0.756 ($P < .001$) for pre- and post-TAA, respectively (Figure 3).

All numerical variables were normally distributed. Mean (SD) vertical intermalleolar distances for pre-TAA, nonarthritic contralateral ankle, and post-TAA were 17.91 (4.79), 18.96 (4.67), and 17.37 (4.76), respectively. The vertical joint line distance means for pre-TAA, nonarthritic contralateral, and post-TAA ankles vertical joint line distance were 26.49 (4.64), 25.47 (4.12), and 26.70 (5.31). In addition, mean (SD) joint line height ratios for the pre-TAA,

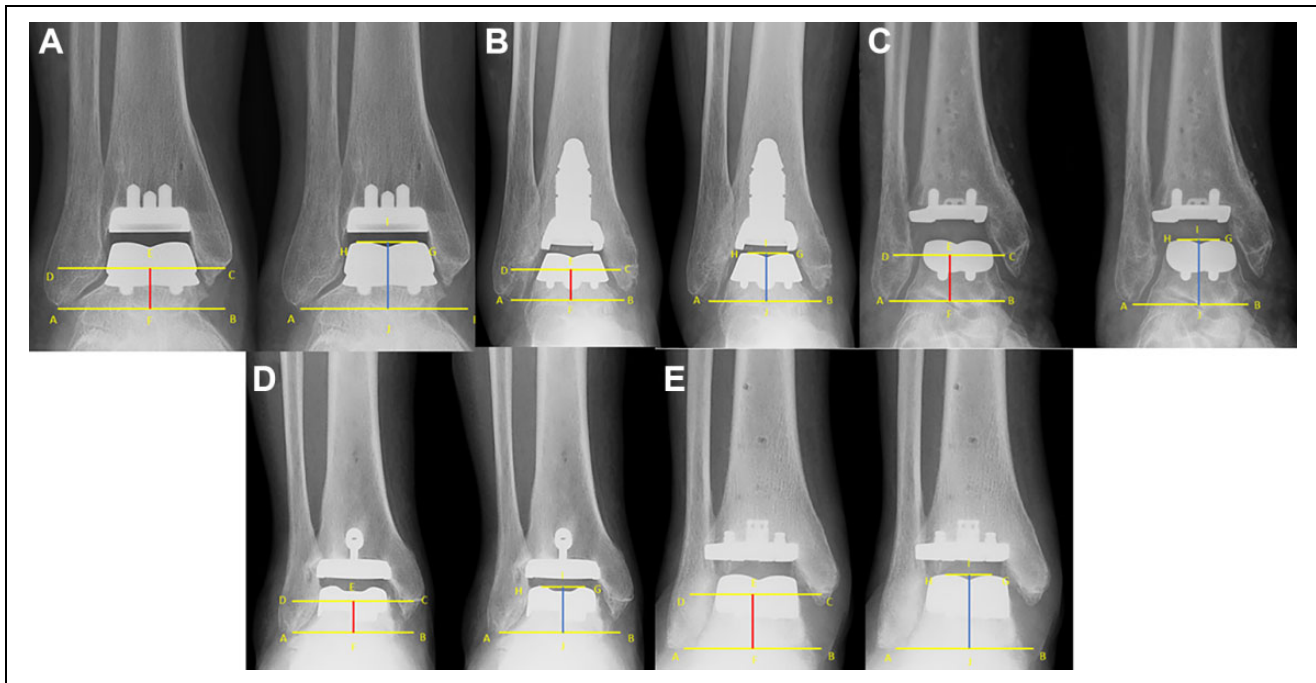


Figure 2. The joint line height ratio post-TAA. The GH line was drawn from the medial and lateral uppermost points of the talar component. The point I was the midpoint of GH. The remaining steps of the measurement were the same as described for the preoperative ankle radiographs. The ratio was calculated as IJ/EF. Total ankle arthroplasty implants are (A) Infinity, (B) INBONE II, (C) Cadence, (D) Salto Talaris, and (E) Vantage.

Table 1. Intra- and Inter-rater Reliability of Radiographic Measurements (n = 112).

Measurements	Intrarater Reliability, r (95% CI)	Inter-rater Reliability, r (95% CI)
Pre-TAA vertical intermalleolar distance	0.984 (0.964, 0.993) ^a 0.982 (0.973, 0.997) ^b	0.933 (0.902, 0.954)
Pre-TAA vertical joint line distance	0.983 (0.961, 0.992) ^a 0.983 (0.975, 0.988) ^b	0.967 (0.934, 0.981)
Nonarthritic contralateral vertical intermalleolar distance	0.983 (0.962, 0.993) ^a 0.985 (0.965, 0.994) ^b	0.992 (0.978, 0.997)
Nonarthritic contralateral vertical joint line distance	0.986 (0.969, 0.994) ^a 0.981 (0.956, 0.992) ^b	0.993 (0.980, 0.998)
Post-TAA vertical intermalleolar distance	0.978 (0.950, 0.990) ^a 0.966 (0.950, 0.977) ^b	0.930 (0.890, 0.955)
Post-TAA vertical joint line distance	0.990 (0.977, 0.995) ^a 0.975 (0.963, 0.983) ^b	0.983 (0.968, 0.990)

Abbreviations: CI, confidence interval; TAA, total ankle arthroplasty.

^aFirst rater.

^bSecond rater.

nonarthritic contralateral ankle, and post-TAA were 1.54 (0.31), 1.39 (0.26), and 1.62 (0.49), respectively (Table 2).

There was a significantly higher joint line height ratio of pre-TAA and post-TAA compared with the nonarthritic contralateral ankle with a mean (95% confidence interval) difference of 0.15 (0.075-0.225) and 0.23 (0.127-0.333) ($P < .001$ and $P < .001$), respectively. There was no significant difference in joint line height ratio between pre- and post-TAA ($P = .15$) (Table 3). According to the subgroup analysis, there was no significant difference between post- and pre-TAA joint line height ratios on each TAA implant ($P = .13, .75, .45, .85, \text{ and } .89$), as well as no significant difference in post-TAA joint line height ratio between each implant ($P = .53$) (Table 4).

Discussion

From the results of this study, we can conclude that the joint line height ratio of the ankle was a reliable measurement method to assess the ankle joint line level. The strong linear correlation of the vertical intermalleolar distance and vertical joint line distance further demonstrated that the ratio between these 2 measurement parameters was practical and could be clinically applicable. The joint line level of end-stage ankle arthritis was higher compared with the nonarthritic contralateral ankle, and the joint line level after TAA continued to be elevated compared with the nonarthritic contralateral ankle. There was no significant difference in joint line level between pre- and post-TAA.

Currently available TAA implants have different amounts of tibial cut depth ranging from 6 to 12 mm, which might

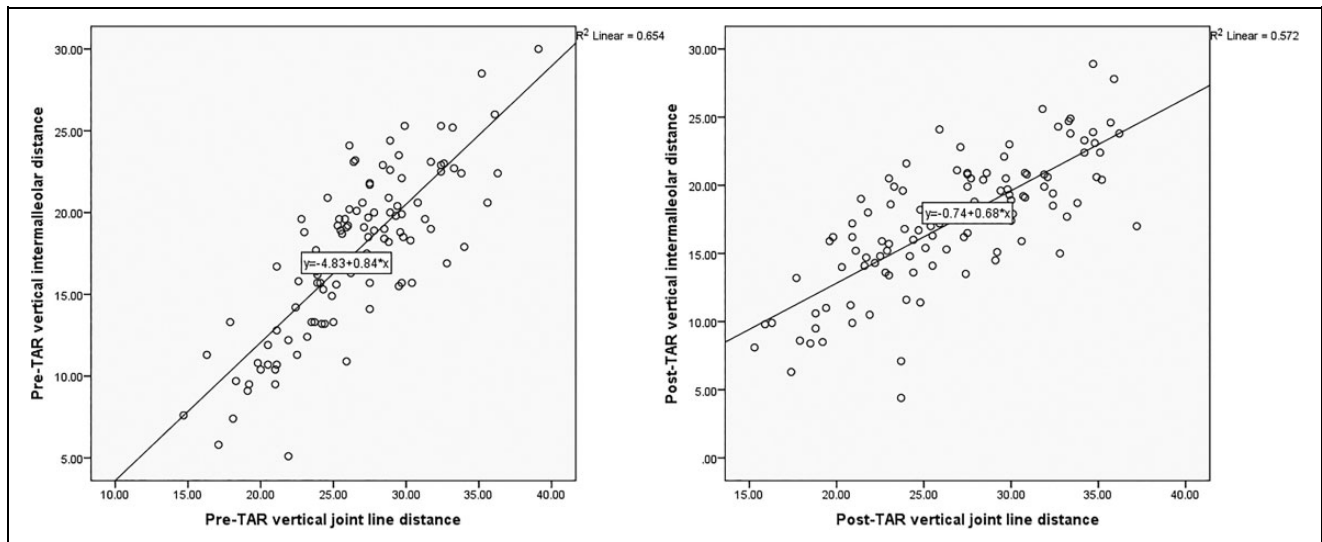


Figure 3. A strong Pearson correlation is shown between vertical intermalleolar distance and joint line distance of pre-TAA and post-TAA anteroposterior weightbearing ankle radiographs.

Table 2. Vertical Intermalleolar Distance, Vertical Joint Line Distance, and Joint Line Height Ratio in Pre-TAA, Nonarthritic Contralateral, and Post-TAA Anteroposterior Ankle Weightbearing Radiographs (n = 112).

Variables	Vertical Intermalleolar Distance, mm, Mean (SD)	Vertical Joint Line Distance, mm, Mean (SD)	Joint Line Height Ratio, Mean (SD)
Pre-TAA	17.9 (4.8)	26.5 (4.6)	1.5 (0.3)
Nonarthritic contralateral ankle	19.0 (4.7)	25.5 (4.1)	1.4 (0.3)
Post-TAA	17.4 (4.8)	26.7 (5.3)	1.6 (0.5)

Abbreviation: TAA, total ankle arthroplasty.

Table 3. Comparison of Joint Line Height Ratio in Pre-TAA, Nonarthritic Contralateral, and Post-TAA Anteroposterior Ankle Weightbearing Radiographs (n = 112).

Radiographic Comparisons	Mean Difference in Joint Line Height Ratio (95% CI)	P Value
Pre-TAA vs nonarthritic contralateral ankle	0.15 (0.075, 0.225)	<.001
Post-TAA vs nonarthritic contralateral ankle	0.23 (0.127, 0.333)	<.001
Pre-TAA vs post-TAA	-0.08 (-0.188, 0.028)	.15

Abbreviations: CI, confidence interval; TAA, total ankle arthroplasty.

affect the differences in joint line level after TAA. According to the subgroup analysis on each implant, there was no significant difference in post-TAA joint line height ratio with regard to the distal tibial resection level on each implant (Table 4). Changing the joint line did not depend on the pre-

Table 4. The Joint Line Height Ratio of Pre-TAA and Post-TAA Based on Implant Type (n = 112).

Implants	Pre-TAA Joint Line Height Ratio	Post-TAA Joint Line Height Ratio	P Value ^a
Infinity (n = 51)	1.47 (0.25)	1.58 (0.28)	.13
Inbone II (n = 19)	1.53 (0.34)	1.57 (0.49)	.75
Cadence (n = 16)	1.66 (0.29)	1.67 (0.26)	.45
Salto Talaris (n = 15)	1.67 (0.65)	1.71 (0.83)	.85
Vantage (n = 11)	1.56 (0.18)	1.55 (0.26)	.89

Abbreviation: TAA, total ankle arthroplasty.

^aOne-way analysis of variance demonstrated that there was no significant difference in post-TAA joint line height ratio based on each implant, P = .53.

setting of the distal tibial resection level of the implant, but instead was directly influenced by the intraoperative decision of the surgeon to adjust the level of the cut based on soft tissue balancing and the degree of deformity correction.

There are many advantages of using this measurement technique to evaluate the joint line level. First, the joint line height is measured on plain radiographs of the ankle which are routinely performed prior to surgery, during the operation (intra-fluoroscopic evaluation), and during the post-operative period following TAA. Therefore, the joint line height ratio could be assessed during all of these phases of care. For the preoperative phase, this measurement could be used to assess the severity of the joint line elevation compared with the nonarthritic contralateral ankle and would provide beneficial information for operative planning with regard to the resection level of the distal tibia.

Second, this measurement method is simple and reproducible; demonstrated by our finding that the intra-class correlation coefficients for both intra- and inter-rater reliability were consistent and rated as excellent for all measurements.

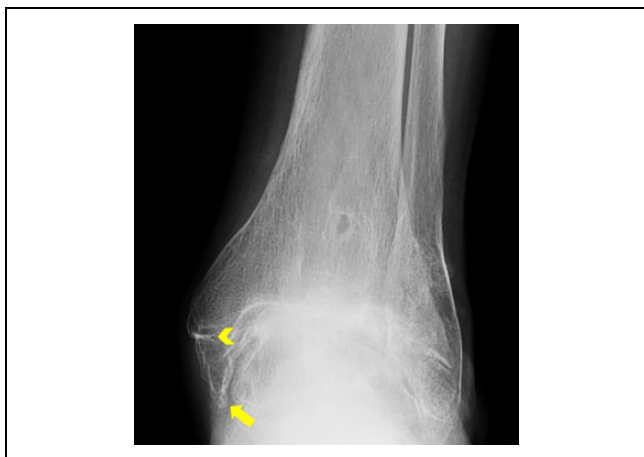

Figure 4. This radiograph demonstrates excessive osteophytes at the anterior colliculus of the medial malleolus which caused difficulty in identification of the landmark (Arrow). However, the tip of posterior colliculus was found to be easier for marking (Arrowhead).

Finally, reporting the joint line height as a ratio eliminates variation due to sex of the patient, size of the ankle, and magnification that could affect the interpretation of the joint line level when using absolute values. Some TKA literature has even suggested using a ratio instead of absolute values for assessing joint line height in order to prevent these same confounding variables from occurring.^{12,14,20}

One concern with this measurement method observed during our study was the identification of a constant landmark at the medial malleolus. During a pilot measurement period, we attempted to use the tip of the anterior colliculus as a landmark. However, in many end-stage ankle arthritis ankle radiographs, there were traction osteophytes and excess bone formations adjacent to the tip of the anterior colliculus, which made finding the exact tip of the anterior colliculus difficult (arrow, Figure 4). Consequently, we changed the landmark to the tip of the posterior colliculus which was not affected by osteophytes and bone formation (arrowhead, Figure 4).

Despite the reproducibility of joint line height ratio, there are some limitations in the clinical application of this measurement method. This method cannot be used in conditions where the constant measurement landmarks between pre- and post-TAA can be changed, including concomitant fibular or medial malleolar osteotomy, or medial or lateral malleolus nonunion. Another issue involves the application of this method for patients with post-traumatic ankle arthritis etiology from a previous ankle fracture. This group of patients might have some degree of medial malleolus or distal fibular malunion that could lead to a difference in the baseline pre-TAA vertical intermalleolar distance and vertical joint line distance when compared with other etiologies.

Based on our findings, end-stage ankle arthritis seems to cause ankle joint line elevation. The sequelae of prolonged ankle arthritis leads to cartilage fibrillation and degradation, subchondral bone sclerosis, cystic changes, and osteophyte

formation.^{18,24} With advanced cartilage loss, the subchondral bone of the distal tibia and the proximal talus come into direct contact. With weightbearing activity, contact on the subchondral bone causes subchondral bone plate injury as well as an adaptive response of the subchondral bone plate of the talus as it becomes thicker.¹⁶ Because the bone density of the talus is higher than that of the distal tibia,³ we believe that this causes greater subchondral bone destruction of the distal tibia compared with the talus. Over time, the ankle joint line becomes elevated because of the distal tibial subchondral bone loss.

In order to restore the ankle joint line level closest to the native level during TAA, the preoperative radiograph might be unreliable and potentially misleading to the surgeon, because the ankle joint line level of a pre-TAA radiograph is already elevated. Therefore, consideration of the joint level measured on the contralateral nonarthritic ankle radiograph is a better option. Additionally, because of the pre-existing joint line elevation due to distal tibial subchondral bone loss from erosion, the amount of intraoperative tibial cut should be minimized as much as possible to prevent further distal tibial bone loss and postoperative ankle joint line elevation.

Comparison of ankle joint line level between pre- and post-TAA demonstrated that the joint line post-TAA was unchanged, and that the joint line remained elevated after surgery compared with the nonarthritic contralateral ankle. To the authors' knowledge, the association between ankle joint line level and clinical outcomes in patients undergoing TAA has not been reported. Bong⁴ and Scuderi et al²² demonstrated that elevation after TKA was related to a decreased range of motion, joint stiffness, and pseudo-patella baja. Elevation of the ankle joint line level might lead to similar consequences. Long-standing elevation of the ankle joint line level could affect the surrounding functional length of soft tissue stabilizers and muscles around the ankle, and with time, alter the interaction between the periarticular ligaments and tendons during gait. Lastly, changes in the joint line may contribute to the progressive stiffness and loss of range of motion observed in patients with end-stage ankle arthritis. Further studies are needed to examine the relationship between the amount of post-TAA ankle joint line elevation and the surrounding ligament and tendons, as well as patient-reported outcomes and postoperative range of motion. This may allow for the establishment of a desired postoperative joint line that may be associated with optimal clinical outcomes after TAA.

To date, this is the first study demonstrating a reliable method to measure ankle joint line level preoperatively and postoperatively. It is also the first study to report ankle joint level characteristics in end-stage ankle arthritis and post-TAA while correlating these levels with the joint line level in the nonarthritic contralateral ankle. However, there are some limitations of this study. First, multiple implant types were used in this cohort, which could affect the level of the cut on the distal tibia. Second, there was variability within

the cohort with regard to the patients' body mass index and demographics, such as age or sex, which could have also affected the ankle joint line level. Lastly, our study only analyzed radiographic data, with no correlation made to clinical outcomes. Therefore, further research evaluating the relationship between joint line elevation and clinical outcomes is still required.

Conclusion

We conclude that this new ankle joint line level measurement method to obtain a joint line height ratio was reliable and could be clinically relevant. The method was found to have excellent intra- and inter-rater reliabilities and had a strong correlation between vertical intermalleolar distance and vertical joint line distance. Patients with end-stage ankle arthritis routinely had ankle joint line elevation when compared to the nonarthritic contralateral ankle. The joint line level after TAA was unchanged compared to preoperative measurements, and remained elevated compared to the nonarthritic contralateral ankle. Therefore, we recommend that surgeons assess contralateral, nonarthritic ankle radiographs when attempting to restore the native ankle joint line level with TAA.

Declaration of Conflicting Interests


The author(s) declared no potential conflicts of interest with respect to the research, authorship, and/or publication of this article. ICMJE forms for all authors are available online.

Funding

The author(s) received no financial support for the research, authorship, and/or publication of this article.

ORCID iD

Thos Harnroongroj, MD,  <https://orcid.org/0000-0003-3330-6869>

Scott J. Ellis, MD,  <https://orcid.org/0000-0002-4304-7445>

References

- Barg A, Bettin CC, Burstein AH, Saltzman CL, Gililland J. Early clinical and radiographic outcomes of trabecular metal total ankle replacement using a transfibular approach. *J Bone Joint Surg Am.* 2018;100(6):505-515.
- Benich MR, Ledoux WR, Orendurff MS, et al. Comparison of treatment outcomes of arthrodesis and two generation of ankle replacement implants. *J Bone Joint Surg Am.* 2017;99(21):1972-1800.
- Bischoff JE, Schon L, Saltzman C. Influence of geometry and depth of resections on bone support for total ankle replacement. *Foot Ankle Int.* 2017;38(9):1026-1034.
- Bong MR, Di Cesare PE. Stiffness after total knee arthroplasty. *J Am Acad Orthop Surg.* 2004;12:164-171.
- Chao EY, Neluheni EV, Hsu RW, Paley D. Biomechanics of malalignment. *Orthop Clin North Am.* 1994;25:379-386.
- Chiu KY, Ng TP, Tang WM, Yau WP. Review article: knee flexion after total knee arthroplasty. *J Orthop Surg.* 2002;10:194-202.
- Cope MR, O'Brien BS, Nanu AM. The influence of the posterior cruciate ligament in the maintenance of joint line in primary total knee arthroplasty: a radiologic study. *J Arthroplasty.* 2002;17:206-208.
- Demetracopoulos C, Halloran JP, Maloof P, Adams SB Jr, Parekh SG. Total ankle arthroplasty in end-stage ankle arthritis. *Curr Rev Musculoskelet Med.* 2013;6:279-284.
- Easley ME, Adams SB JR, Hembree WC, DeOrio JK. Results of total ankle arthroplasty. *J Bone Joint Surg Am.* 2010;93:1455-1468.
- Ee G, Pang HN, Chong HC, Tan MH, Lo NN, Yeo SJ. Computer navigation is a useful intra-operative tool for joint line measurement in total knee arthroplasty. *Knee.* 2013;20:256-262.
- Gougoulias N, Khanna A, Maffulli N. How successful are current total ankle replacements? A systematic review of the literature. *Clin Orthop Relat Res.* 2010;468:199-208.
- Iacono F, Lo Presti M, Bruni D, et al. The adductor tubercle: a reliable landmark for analyzing the level of the femorotibial joint line. *Knee Surg Sports Traumatol Arthrosc.* 2013;21:2725-2729.
- Jawhar A, Hutter K, Scharf HP. Are joint line changes after primary navigated total knee arthroplasty predictable? *J Orthop Sci.* 2015;20:93-100.
- Luyckx T, Beckers L, Colyn W, Vanderneucker H, Bellemans J. The adductor ratio: a new tool for joint line reconstruction in revision TKA. *Knee Surg Sports Traumatol Arthrosc.* 2014;22(12):3028-3033.
- Martin JW, Whiteside LA. The influence of joint line position on knee stability after condylar knee arthroplasty. *Clin Orthop Relat Res.* 1990;259:146-156.
- Nakasa T, Adachi N, Kato T, Ochi M. Correlation between subchondral bone plate thickness and cartilage degeneration in osteoarthritis of the ankle. *Foot Ankle Int.* 2014;35(12):1341-1349.
- NieuweWeme RA, van Solinge G, N Doornberg J, Siersevelt I, Haverkamp D, Doets HC. Total ankle replacement for post-traumatic arthritis. Similar outcome in postfracture and instability arthritis: a comparison of 90 ankles. *Acta Orthop.* 2015;86(4):401-406.
- Nuki G. Osteoarthritis: a problem of joint failure. *Z Rheumatol.* 1999;58(3):142-147.
- Rippstein PF, Huber M, Coetzee JC, Naal FD. Total ankle replacement with use of a new three-component implant. *J Bone Joint Surg Am.* 2011;93(15):1426-1435.
- Romero J, Seifert B, Reinhardt O, Ziegler O, Kessler O. A useful radiologic method for preoperative joint-line determination in revision total knee arthroplasty. *Clin Orthop Relat Res.* 2010;468:1279-1283.
- Sarmah SS, Patel S, Hossain FS, Haddad FS. The radiological assessment of total and unicompartmental knee replacements. *J Bone Joint Surg Br.* 2012;94:321-329.

22. Scuderi GR. The stiff total knee arthroplasty: causality and solution. *J Arthroplasty*. 2005;20:23-26.
23. Selvarajah E, Hooper G. Restoration of the joint line in total knee arthroplasty. *J Arthroplasty*. 2009;24:1099-1102.
24. Wierworski M, Dopke K, Steiger C, Valderrabano V. Muscular atrophy of the lower leg in unilateral post traumatic osteoarthritis of the ankle joint. *Int Orthop*. 2012;36:2079-2085.
25. Wyss TF, Schuster AJ, Munger P, Pfluger D, Wehrli U. Does total knee joint replacement with the soft tissue balancing surgical technique maintain the natural joint line? *Arch Orthop Trauma Surg*. 2006;126:480-486.
26. Yang JH, Seo JG, Moon YW, Kim MH. Joint line changes after navigation-assisted mobile-bearing TKA. *Orthopedics*. 2009;32:35-39.