




Available online at
ScienceDirect
www.sciencedirect.com

Elsevier Masson France
EM|consulte
www.em-consulte.com/en



Original article

Does arthrodesis of the first metatarsophalangeal joint correct the intermetatarsal M1M2 angle? Analysis of a continuous series of 208 arthrodeses fixed with plates



F. Dalat^{a,*}, F. Cottalorda^b, M.-H. Fessy^{a,c}, J.-L. Besse^{a,c}

^a Service de chirurgie orthopédique, traumatologique et de médecine du sport, hospices civils de Lyon, centre hospitalier Lyon-Sud, 69495 Pierre-Bénite cedex, France

^b Service de chirurgie orthopédique et traumatologique, CHU Gabriel Montpied, Clermont-Ferrand, France

^c Laboratoire de biomécanique et mécanique des chocs, université Lyon 1, IFSTTAR, LBMC UMR-T 9406, 69675 Bron cedex, France

ARTICLE INFO

Article history:
 Received 23 October 2014
 Accepted 8 June 2015

Keywords:
 Hallux
 Metatarsophalangeal arthrodesis
 M1M2 angle
 M1P1 angle

ABSTRACT

Introduction: First-ray metatarsophalangeal arthrodesis is a classic surgical procedure in the treatment of severe hallux valgus, hallux rigidus, revision surgery, and inflammatory arthritis. The objective of this study was to verify if metatarsophalangeal plate arthrodesis could correct the M1M2 intermetatarsal angle.

Material and methods: This prospective and continuous series (June 2007 to March 2011) included 208 patients (48% severe and/or arthritic hallux valgus, 18% hallux rigidus, 16% rheumatoid forefoot, 13% surgical revision of the first ray, 5% hallux varus), with a mean age of 62.4 ± 9.9 years (range, 19–87 years). All the patients were operated on by a senior surgeon with the same technique: spherical avivement of the joint surfaces using reamers, osteosynthesis with an anatomic plate (Fyxis-Biotech™) in Ti.6Al.4V alloy prebent to 5° with a phalangeal arm to receive an oblique metatarsophalangeal screw in compression, in addition to four 2.7-mm nonlocking dorsal screws. The full-scale preoperative and intraoperative angle measurements were taken on AP and lateral X-rays of the weightbearing foot, as related to the etiology and the severity of the preoperative metatarsus varus (M1M2 < 15° , M1M2 15– 19° , M1M2 $\geq 20^\circ$). The statistical analysis was done using the StatView software.

Results: The mean follow-up was 18.6 ± 12.4 months (range, 2–76 months). Nearly all of the arthrodesis patients (97%) achieved bone union, and 5% of the plates were removed. The M1P1 angle decreased from $33.8 \pm 19.7^\circ$ (range, -45° to -67°) preoperatively to $13.3 \pm 5.3^\circ$ (range, 0– 32°) at the last follow-up, and the M1M2 angle from $14.2 \pm 5.4^\circ$ (range, 0– 26°) to $6.5 \pm 2.3^\circ$ (range, 0– 12°). The preoperative M1M2 angle was < 15° in 97 patients, 15– 19° for 78 patients, and $\geq 20^\circ$ for the 33 others; at the last follow-up it was $5.8 \pm 2.1^\circ$ (range, 0– 10°), $6.7 \pm 2.2^\circ$ (0– 10°), and $8.1 \pm 2.4^\circ$ (3– 12°), respectively. No correction of the metatarsus varus was demonstrated in relation to etiology. The M1M2 angle was > 10° in only two patients (one case of rheumatoid arthritis and one case of severe hallux valgus): 0.9%.

Discussion: These results show that isolated metatarsophalangeal arthrodesis of the first ray can correct metatarsus varus even in substantial deformations in any etiology.

Level of proof: Level II cohort study.

© 2015 Elsevier Masson SAS. All rights reserved.

1. Introduction

Metatarsophalangeal arthrodesis of the first ray (MTP-1) is a classic technique in the treatment of first-ray pathologies [1–3].

Although it is not proposed in first-line treatment for younger subjects, it remains indicated in case of severe hallux valgus or with severe arthritic lesions, hallux rigidus, surgical revision, or inflammatory arthritis [4–8].

This procedure corrects the angle between the first metatarsal and the first phalanx of the hallux (M1P1) and the angle between the first and second metatarsal or the intermetatarsal M1M2 angle (M1M2) [3,9,10]. Correction of the M1M2 angle is particularly important because if it is undercorrected, the patient preserves a wide forefoot, a space between the first and second toes that is both

* Corresponding author. Service de chirurgie orthopédique, traumatologique et de médecine du sport, centre hospitalier Lyon-Sud, chemin du Grand-Revoyet, 69495 Pierre-Bénite cedex, France. Tel.: +04 7886 5930; fax: +04 7886 5934.

E-mail address: fred.dalat@hotmail.fr (F. Dalat).

unesthetic and uncomfortable when wearing shoes. However, in feet with a very high preoperative M1M2 angle, MTP-1 arthrodesis alone could be insufficient because the wide metatarsal varus angle persists [1,11]. Some authors such as Rippstein et al. [12] recommend metatarsal osteotomy in addition to arthrodesis when the preoperative M1M2 angle is greater than 10°. To date there has been no consensus on the best surgical procedure when the M1M2 angle is very wide.

This study hypothesized that isolated MTP-1 arthrodesis of the first ray suffices to correct M1P1 and M1M2 angles simultaneously, including in substantial deformities and independently of the etiology of the deformity. This study analyzed the position of the arthrodesis and the correction of the first-ray angles as well as the time to bone union and the postoperative complications in a continuous series.

2. Material and methods

Between June 2007 and March 2011, we conducted a prospective and continuous study on a total of 208 patients operated for plate MTP-1 arthrodesis. All the patients included in the study underwent preoperative clinical and radiological assessment and all were seen postoperatively following the same radiological and clinical protocol at 45 days, 3 months, 1 year, and at the last follow-up.

2.1. Population

The mean age at surgery was 62.4 ± 9.9 years (range, 19–87 years). The mean follow-up was 18.6 ± 12.4 months (range, 3–76 months). The cohort included 89% women. In addition, 20% of the patients had already undergone forefoot surgery before the arthrodesis. The etiologies were distributed into: 48% severe hallux valgus (M1P1 angle $> 40^\circ$) and/or arthritic hallux valgus, 18% hallux rigidus, 16% rheumatoid foot, 13% surgical revision of the first ray, and 5% hallux varus. The postoperative complications and the surgical revision cases were identified and analyzed.

2.2. Surgical technique

All the patients were operated by the same senior surgeon specialized in foot and ankle surgery (JLB) using the same surgical technique. A medial approach exposing the dorsal side of the base of the first phalanx and the first metatarsal was used. After lateral arthrolisis (including release of the dorsal extensor hallucis longus muscle, resection of the suspensor ligament of the lateral sesamoid and the lateral collateral ligament on the lateral epicondyle of the first metatarsal), spherical freshening of the joint surfaces was performed using concave and convex reamers turning at a slow speed. After freshening of the sesamoids, the arthrodesis was osteosynthesized with an anatomical plate (Fyxis-Biotech™) in Ti.6Al.4V alloy prebent at 5° including a phalangeal arm for an oblique metatarsophalangeal screw in compression, complementary to the four 2.7-mm dorsal screws. The screws were not locked in the plate. Proper positioning of the MTP-1 arthrodesis was checked intraoperatively using fluoroscopy.

After surgery, all patients were recommended immediate complete weightbearing protected by a postoperative walking boot (Sober™) for 6 weeks. The bandage and separate stitches were removed at the check-up 3 weeks after surgery.

2.3. Radiological measurements

The preoperative and postoperative radiographic workup consisted in two X-rays with load, magnified 100%: one dorsal-plantar view and one lateral view of the operated foot (Figs. 1 and 2). Bone

union was confirmed on X-ray (three corticals out of four). The AP M1M2 and M1P1 angles were measured according to the recommendations of the American Orthopaedic Foot and Ankle Society [13,14] by an independent observer (FD) on X-rays taken during the follow-up at 3 months, once MTP-1 arthrodesis bone union had been acquired, 12 months after surgery, and at the last follow-up. The pre- and postoperative absolute values of the intermetatarsal angle were studied, as was the difference between these two measurements. The study also investigated the positioning of the first ray by measuring the APM1P1 angles. The results were analyzed for the overall series and for the different etiologies and the amplitude of the preoperative metatarsus varus (M1M2 $< 15^\circ$, M1M2 $15\text{--}19^\circ$, M1M2 $\geq 20^\circ$).

2.4. Statistical analysis

The statistical analysis was performed using StatView™ (SAS Institute Inc., Cary, NC, USA). The quantitative variables were studied using the Student *t*-test after having checked that the sample was normally distributed. To compare more than two groups of quantitative variables according to a normal distribution, an ANOVA test was applied. The qualitative variables were studied using the Chi-square test. The significance threshold was established for $p < 0.05$. A relation between the pre- and postoperative intermetatarsal angles was sought by drawing a regression curve using the least-squares method. The correlation coefficient of this curve was analyzed.

3. Results

The mean follow-up was 18.6 ± 12.4 months (range, 3–76 months) for the overall series. This was not statistically different between the different etiology groups or according to the severity of the preoperative deformity (Tables 1 and 2).

3.1. Radiological analysis

In the overall series, there was a significant reduction in the M1P1 and M1M2 angles, respectively decreasing from a preoperative level of $33.9^\circ \pm 19.7^\circ$ (range, -45 to 67°) to a postoperative level of $13.3^\circ \pm 5.3^\circ$ (range, $0\text{--}32^\circ$) at the last follow-up ($P < 0.0001$) and from $14.2^\circ \pm 5.4^\circ$ (range, $0\text{--}26^\circ$) preoperatively to $6.5^\circ \pm 2.3^\circ$ (range, $0\text{--}12^\circ$) at the last follow-up ($P < 0.0001$) (Figs. 1 and 2). There was no significant difference between the results obtained for the M1P1 and M1M2 angles at 3 months and 12 months postoperative and at the last follow-up (Table 1). Within each etiological group and each deformity severity group, the same significant difference was demonstrated for the pre- and postoperative M1P1 and M1M2 angles (Table 1). There was no significant difference for the postoperative M1M2 angle between the different etiologies except between the hallux valgus and hallux rigidus groups, $6.9^\circ \pm 2.3^\circ$ (range, $0\text{--}12^\circ$) versus $5.3^\circ \pm 2.6^\circ$ (range, $0\text{--}9^\circ$) ($P = 0.035$), respectively.

The more the preoperative M1M2 angle increased the greater the gain in metatarsus varus was (M1M2 gain = difference between the pre- and postoperative M1M2 angle). However, statistically, the greater the metatarsus varus was, the higher the postoperative M1M2 was, but remaining less than 10° (Table 2). There was no correlation between the preoperative metatarsus varus value and the value obtained postoperatively because the correlation coefficient of the regression line was 0.33 (Fig. 3). Only two patients (one with rheumatoid arthritis and one with severe arthritic hallux valgus) out of 208 preserved an M1M2 angle greater than 10° ; they presented associated first-ray cuneometatarsal arthritis (Fig. 4).

Table 1
Pre- and postoperative M1P1 and M1M2 angles for the overall series and according to etiology.

	Preoperative		3 months postoperative		12 months postoperative		At last follow-up		
	M1M2	AP M1P1	M1M2	AP M1P1	M1M2	M1P1 face	Follow-up (months)	M1M2	AP M1P1
Hallux valgus	16.6 ± 4.3 (5–26)	43.4 ± 11.3 (9–67)	7.7 ± 3.3 (1–12)	15.2 ± 5.5 (0–32)	7.1 ± 2.8 (1–12)	15.1 ± 5.4 (0–32)	17.5 ± 9.3 (3–48)	6.9 ± 2.3 (0–12)	15.0 ± 5.3 (0–32)
Hallux rigidus	9.9 ± 4.5 (4–22)	17.1 ± 7.9 (–1–40)	6.7 ± 1.8 (2–8)	9.7 ± 3.3 (4–18)	6.5 ± 1.9 (1–9)	9.7 ± 3.4 (1–18)	13.4 ± 9.8 (2–52)	6.4 ± 2.1 (0–10)	9.7 ± 3.6 (0–18)
Rheumatoid forefoot	15.4 ± 4.3 (5–25)	42.2 ± 10.6 (20–64)	7.2 ± 2.6 (2–12)	13.6 ± 5.4 (4–27)	6.7 ± 2.5 (1–12)	13.2 ± 5.2 (0–24)	26.8 ± 17.2 (5–76)	6.1 ± 2.3 (2–12)	12.7 ± 4.9 (0–22)
Hallux varus	4.2 ± 3.6 (0–10)	–23.5 ± 12.6 (–45 to –10)	6.3 ± 2.0 (4–10)	10.4 ± 4.0 (4–18)	5.5 ± 2.2 (4–9)	10.8 ± 3.8 (4–18)	15.2 ± 11.3 (2–38)	5.3 ± 2.6 (0–9)	11.1 ± 3.8 (5–19)
Surgical revision	13.4 ± 4.4 (3–21)	31.9 ± 14.1 (–5 to 50)	6.2 ± 2.5 (0–12)	13.9 ± 4.6 (7–24)	6.2 ± 2.4 (0–10)	13.8 ± 4.9 (5–24)	21.5 ± 14.6 (3–63)	6.0 ± 2.3 (2–10)	13.4 ± 5.2 (5–23)
Overall series	14.2 ± 5.4 (0–26)	33.9 ± 19.7 (–45 to 67)	7.3 ± 3.2 (0–12)	13.5 ± 5.4 (0–32)	6.9 ± 2.7 (0–12)	13.5 ± 5.4 (0–32)	18.6 ± 12.4 (2–76)	6.5 ± 2.3 (0–12)	13.3 ± 5.3 (0–32)

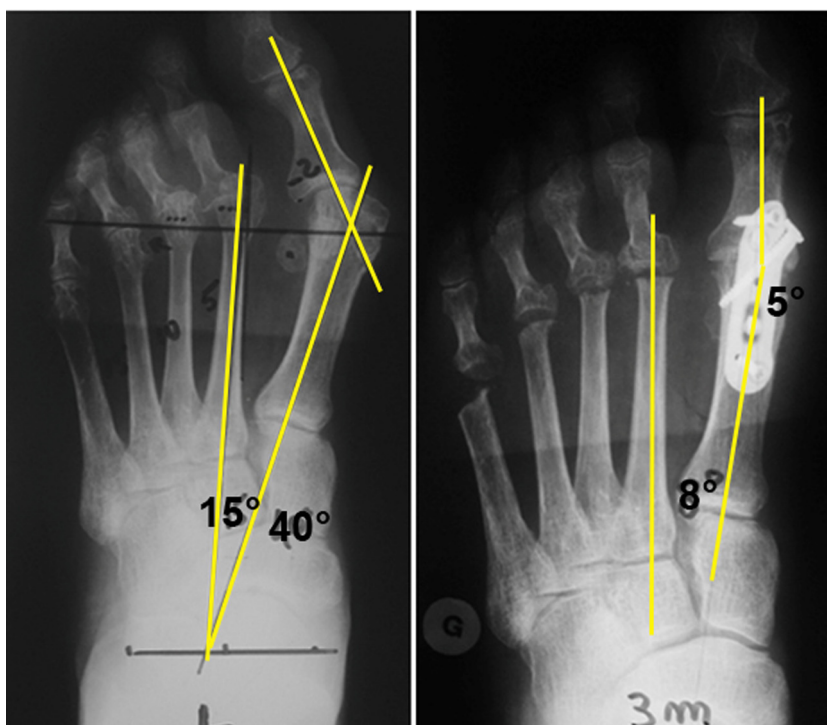


Fig. 1. MTP-1 arthrodesis with resection of the metatarsal heads in a female patient with rheumatoid arthritis: preoperative AP dorsal-plantar X-ray with load (left, M1P1 40°, M1M2 15°) and at 3 months postoperative (right, M1P1 5°, M1M2 8°).

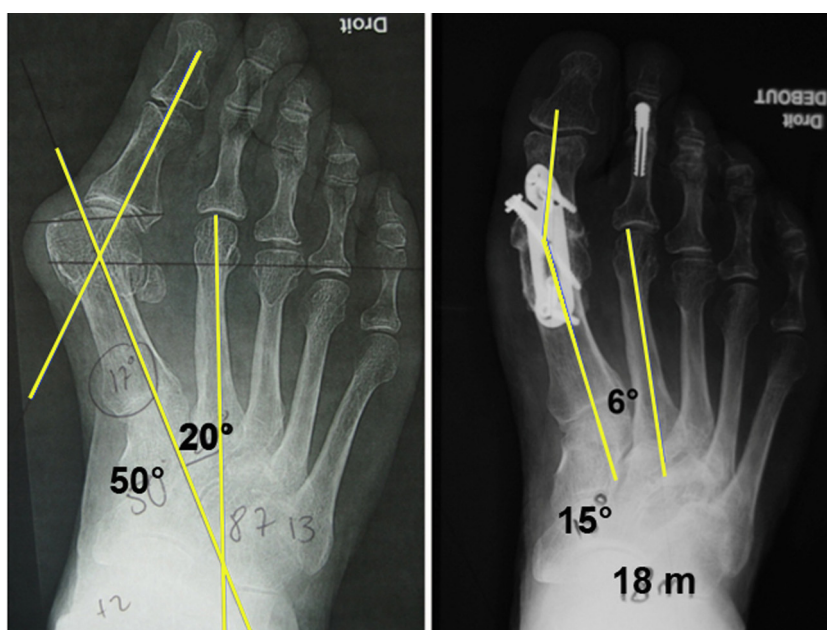


Fig. 2. Stage IV hallux valgus in a 78-year-old female patient: preoperative AP dorsal-plantar X-ray with load (left, M1P1 50°, M1M2 20°) and at 18 months postoperative (right, M1P1 15°, M1M2 6°).

Table 2
Pre- and postoperative M1P1 and M1M2 angles according the severity of the preoperative M1M2 angle.

	Number of subjects	Mean follow-up (months)	Preoperative		Postoperative at last follow-up		Gain in pre- and postoperative M1M2 angle
			M1M2	M1P1 face	M1M2	M1P1 face	
M1M2 < 15°	97	17.3 ± 11.5 (3–63)	9.5 ± 3.5 (0–14)	23.6 ± 21.7 (–4–60)	5.8 ± 2.1 (0–10)	12.5 ± 4.8 (0–26)	3.7 ± 3.9 (–5–11)
15° ≤ M1M2 < 20°	78	19.5 ± 14.3 (3–76)	16.8 ± 1.4 (15–19)	41.6 ± 12.9 (–5–67)	6.7 ± 2.3 (0–12)	14.4 ± 5.9 (0–32)	10.1 ± 2.4 (4–19)
M1M2 ≥ 20°	33	20.5 ± 9.8 (3–41)	22.0 ± 2.1 (20–26)	45.6 ± 9.5 (24–60)	8.0 ± 2.3 (3–12)	13.0 ± 4.6 (3–25)	14.0 ± 3.3 (10–22)
Overall series	208	18.6 ± 12.4 (3–76)	14.2 ± 5.4 (0–26)	33.9 ± 19.7 (–45–67)	6.5 ± 2.3 (0–12)	13.3 ± 5.3 (0–32)	7.7 ± 5.2 (–5–22)

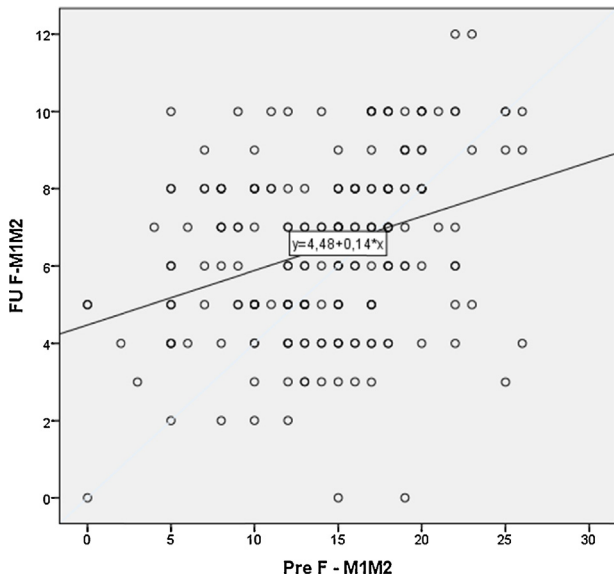


Fig. 3. Regression line according to the least-squares method between the pre- and postoperative M1M2 values.

3.2. Complications

Two cases of septic complications secondary to scarring problems were noted. Fusion of the arthrodesis was obtained radiologically at 3 months postoperative in 97.1% of the cases. Six cases (2.9%) of malunion were noted. At the last follow-up, the plate had to be removed in 11 patients (5.3%): three cases for malunion, three other cases for impingement with the material, three cases for screw migration, and two cases of sepsis. In the malunion cases, removing the material did not cause changes in the M1P1 and M1M2 angles.

No fatigue fracture was recorded but three patients fractured the first ray traumatically (two fractures of the first metatarsal and one fracture of the first phalanx). These patients were all treated orthopaedically, leading to bone union.

4. Discussion

This continuous and prospective series showed that isolated MTP-1 arthrodesis provided simultaneous correction of the M1P1 and M1M2 angles, including in patients with a preoperative M1M2 angle greater than 20°. Only two patients retained an M1M2 angle greater than 10° at the last follow-up. Union of the arthrodesis was obtained in 97.1% of the cases at 3 months postoperative. Plate removal was required in 5.3% of the cases for malunion, infection, or impingement between soft tissues and the orthopaedic material. A high rate of the patients (88.9%) were satisfied or very satisfied with the intervention.

The biases of the study are related to the presence of diverse preoperative etiologies and deformities. To limit this bias, the results were analyzed by etiology and in creating groups according to the amplitude of the preoperative M1M2 angle.

The main strength of this study is its homogeneity: a prospective, continuous series, patients operated with the same surgical technique, and identical postoperative follow-up by a single senior surgeon specialized in foot and ankle surgery (JLB).

MTP-1 arthrodesis is a surgical technique that is widely indicated and recognized in the treatment of severe and/or arthritic hallux valgus [1–3], surgical revisions, and severe deformities of the first ray whatever the etiology may be [4–8]. A number of authors have reported in the literature that MTP-1 arthrodesis can correct the M1P1 angle as well as metatarsus varus [3,9,10,15]. However, the mechanism of correction of metatarsus varus is poorly known and few authors have contributed an explanation for this phenomenon [9,10]. With the correction and fusion of the MTP-1 joint, the adductor of the hallux acts through the conjoint tendon of the lateral sesamoid, the adductor of the hallux on the unit made up of the first phalanx and the first metatarsal. After fusion of the MTP-1 joint, the lever arm of the adductor of the hallux is increased and its force is transmitted to the first metatarsal, correcting the M1M2 angle [9]. This force, combined with a mobile C1M1 joint, reduces the M1M2 intermetatarsal angle [10].

In the literature, M1M2 angle correction varies between 4.0° and 8.2° depending on the study [9,10,16–18]. The results reported herein are within this range in that we found a gain of $7.7° ± 5.2°$ (range, –5 to 22). However, these results contradict those reported

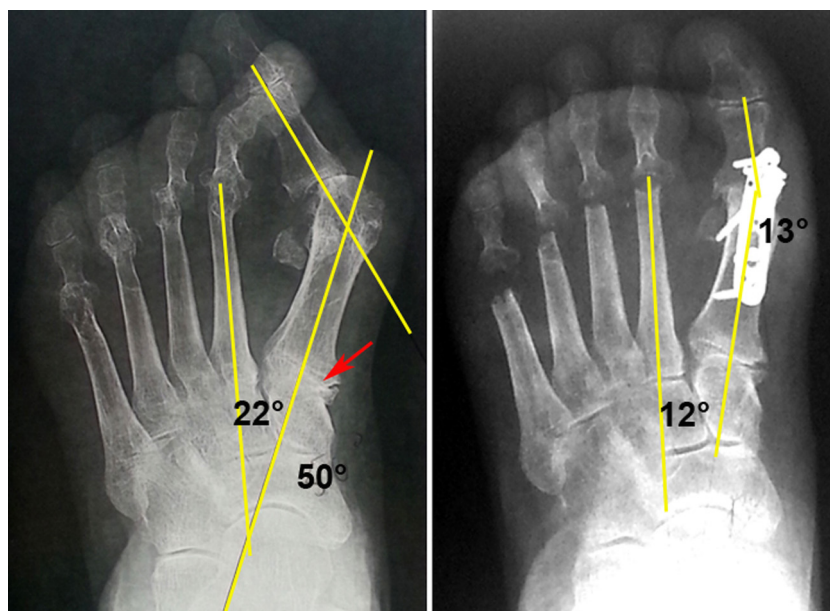


Fig. 4. MTP-1 arthrodesis with resection of the metatarsal heads in a female patient with rheumatoid arthritis and presence of C1M1 arthritis: preoperative AP dorsal-plantar X-ray with load (left, M1P1 50°, M1M2 22°) and at 12 months postoperative (right, M1P1 13°, M1M2 12°).

by Rippstein et al. [12], who, based on a small series of 18 cases, suggested systematically associating a proximal procedure at the first metatarsal (osteotomy or Lapidus) with MTP1 arthrodesis to obtain better correction of metatarsus varus. In this series, the preoperative M1M2 angle decreased from 18.8° to 4.6° at a mean 14.2 months follow-up. They reported no bone union problems. In contrast, we confirm in this large prospective series that MTP1 arthrodesis corrects metatarsus varus without needing to associate a proximal procedure on the first metatarsal. This conclusion is shared by other authors [13–18]. The only indication for associated C1M1 arthrodesis that seems legitimate is the case of patients presenting a wide M1M2 angle associated with irreducible cuneometatarsal arthritis (C1M1 stiffness). Our two failures presented this configuration with an M1M2 angle at the last follow-up greater than 10°.

We have demonstrated that the higher the preoperative M1M2 is, the greater the correction is (Table 2). These results differ from two cohorts with fewer subjects [9,19]. Moreover, for Pydah et al., there is a finite limit to the improvement of the M1M2 angle and they propose a regression line predicting the residual metatarsal in relation to the preoperative M1M2 angle [10]. This correlation was not found in our study because the correlation coefficient is 0.33. However, this author does not recommend adding a procedure to MTP-1 arthrodesis.

We noted 97.1% fusion in MTP-1 arthrodesis in our series including primary and revision surgeries. This result matches the results found in the literature, which vary according to the osteosynthesis used, the type of refreshing, and the etiology of the deformity [20,21].

5. Conclusion

This study confirms the data in the literature: MTP1 arthrodesis is an intervention that can simultaneously correct the M1M2 and M1P1 angles, including in substantial deformities. The greater the preoperative metatarsus varus, the greater the gain obtained without demonstrating a correlation between the pre- and post-operative M1M2 angle. We therefore reserve complementary cuneometatarsal arthrodesis associated with MTP-1 arthrodesis in the very rare cases of osteoarthritis of the cuneometatarsal joint associated with a major increase in the M1M2 angle.

Disclosure of interest

Jean-Luc BESSE: consultancy contract with Biotech-Wright.

The other authors declare that they have no conflicts of interest concerning this article.

References

- [1] Coughlin MJ. Hallux valgus. *J Bone Joint Surg Am* 1996;78(6):932–66.
- [2] Mann RA, Oates JC. Arthrodesis of the first metatarsophalangeal joint. *Foot Ankle* 1980;1(3):159–66.
- [3] Coughlin MJ, Grebing BR, Jones CP. Arthrodesis of the first metatarsophalangeal joint for idiopathic hallux valgus: intermediate results. *Foot Ankle Int* 2005;26(10):783–92.
- [4] Sammarco GJ, Idusuyi OB. Complications after surgery of the hallux. *Clin Orthop Relat Res* 2001;(391):59–71.
- [5] Coughlin MJ. Rheumatoid forefoot reconstruction. A long-term follow-up study. *J Bone Joint Surg Am* 2000;82(3):322–41.
- [6] Grimes JS, Coughlin MJ. First metatarsophalangeal joint arthrodesis as a treatment for failed hallux valgus surgery. *Foot Ankle Int* 2006;27(11):887–93.
- [7] Mann RA, Thompson FM. Arthrodesis of the first metatarsophalangeal joint for hallux valgus in rheumatoid arthritis. *J Bone Joint Surg Am* 1984;66(5):687–92.
- [8] Pinney SJ, Song KR, Chou LB. Surgical treatment of severe hallux valgus: the state of practice among academic foot and ankle surgeons. *Foot Ankle Int* 2006;27(12):1024–9.
- [9] Cronin JJ, Limbers JP, Kutty S, Stephens MM. Intermetatarsal angle after first metatarsophalangeal joint arthrodesis for hallux valgus. *Foot Ankle Int* 2006;27(2):104–9.
- [10] Pydah SKV, Toh EM, Sirikonda SP, Walker CR. Intermetatarsal angular change following fusion of the first metatarsophalangeal joint. *Foot Ankle Int* 2009;30(5):415–8.
- [11] McKeever DC. Arthrodesis of the first metatarsophalangeal joint for hallux valgus, hallux rigidus, and metatarsus primus varus. *J Bone Joint Surg Am* 1952;34-A(1):129–34.
- [12] Rippstein PF, Park YU, Naal FD. Combination of first metatarsophalangeal joint arthrodesis and proximal correction for severe hallux valgus deformity. *Foot Ankle Int* 2012;33(5):400–5.
- [13] Smith RW, Reynolds JC, Stewart MJ. Hallux valgus assessment: report of research committee of American Orthopaedic Foot and Ankle Society. *Foot Ankle* 1984;5(2):92–103.
- [14] Coughlin MJ, Saltzman CL, Nunley 2nd JA. Angular measurements in the evaluation of hallux valgus deformities: a report of the ad hoc committee of the American Orthopaedic Foot & Ankle Society on angular measurements. *Foot Ankle Int* 2002;23(1):68–74.
- [15] Dayton P, Feilmeier M, Hunziker B, Nielsen T, Reimer RA. Reduction of the intermetatarsal angle after first metatarsal phalangeal joint arthrodesis: a systematic review. *J Foot Ankle Surg* 2014;53(5):620–3.
- [16] Von Salis-Soglio G, Thomas W. Arthrodesis of the metatarsophalangeal joint of the great toe. *Arch Orthop Trauma Surg* 1979;95(1–2):7–12.
- [17] Riggs Jr SA, Johnson Jr EW. McKeever arthrodesis for the painful hallux. *Foot Ankle* 1983;3(5):248–53.
- [18] Humbert JL, Bourbonnière C, Laurin CA. Metatarsophalangeal fusion for hallux valgus: indications and effect on the first metatarsal ray. *Can Med Assoc J* 1979;120(8), 937–941, 956.
- [19] Mann RA, Katcherian DA. Relationship of metatarsophalangeal joint fusion on the intermetatarsal angle. *Foot Ankle* 1989;10(1):8–11.
- [20] Tourné Y, Saragaglia D, Zattara A, Maire JP, Picard F, Montbarbon E, et al. Hallux valgus in the elderly: metatarsophalangeal arthrodesis of the first ray. *Foot Ankle Int* 1997;18(4):195–8.
- [21] Besse JL, Chouteau J, Laptou D. Arthrodesis of the first metatarsophalangeal joint with ball and cup reamers and osteosynthesis with pure titanium staples. Radiological evaluation of a continuous series of 54 cases. *Foot Ankle Surg* 2010;16(1):32–7.