

Angiosomes of the Foot and Ankle and Clinical Implications for Limb Salvage: Reconstruction, Incisions, and Revascularization

Christopher E. Attinger,
M.D.

Karen Kim Evans, M.D.

Erwin Bulan, M.D.

Peter Blume, D.P.M.

Paul Cooper, M.D.

Washington, D.C.; New Haven,
Conn.; and Millburn, N.J.

Background: Ian Taylor introduced the angiosome concept, separating the body into distinct three-dimensional blocks of tissue fed by source arteries. Understanding the angiosomes of the foot and ankle and the interaction among their source arteries is clinically useful in surgery of the foot and ankle, especially in the presence of peripheral vascular disease.

Methods: In 50 cadaver dissections of the lower extremity, arteries were injected with methyl methacrylate in different colors and dissected. Preoperatively, each reconstructive patient's vascular anatomy was routinely analyzed using a Doppler instrument and the results were evaluated.

Results: There are six angiosomes of the foot and ankle originating from the three main arteries and their branches to the foot and ankle. The three branches of the posterior tibial artery each supply distinct portions of the plantar foot. The two branches of the peroneal artery supply the anterolateral portion of the ankle and rear foot. The anterior tibial artery supplies the anterior ankle, and its continuation, the dorsalis pedis artery, supplies the dorsum of the foot. Blood flow to the foot and ankle is redundant, because the three major arteries feeding the foot have multiple arterial-arterial connections. By selectively performing a Doppler examination of these connections, it is possible to quickly map the existing vascular tree and the direction of flow.

Conclusions: Detailed knowledge of the vascular anatomy of the foot and ankle allows the plastic surgeon to plan vascularly sound reconstructions, the foot and ankle surgeon to design safe exposures of the underlying skeleton, and the vascular surgeon to choose the most effective revascularization for a given wound. (*Plast. Reconstr. Surg.* 117 (Suppl.): 261S, 2006.)

Knowledge of vascular anatomy of the foot and ankle and an understanding of the dynamic nature of that vasculature are essential for limb salvage. The angiosome principle was defined by Ian Taylor's landmark anatomic study and divides the body into individual angiosomes: three-dimensional blocks of tissue fed by "source" arteries. The foot and ankle are composed of six such distinct angiosomes. Because the foot and ankle comprise an end organ, their main arteries have numerous direct arterial-arterial connections that allow alternative routes of blood flow to develop

if the direct route is disrupted or compromised.

Understanding the boundaries of the angiosome and the vascular connections among its source arteries provides the basis for designing incisions and tissue exposure that preserve blood flow for the surgical wound to heal. That knowledge also allows the surgeon to predict which pedicled flap can be successfully harvested or whether a given amputation will heal. Finally, this knowledge should help guide the vascular surgeon in choosing the bypass or endovascular procedure that has the best chance of healing existent ischemic ulcers.

From the Limb Center, Georgetown University Medical Center; the Department of Surgery, Yale University; and private practice.

Received for publication November 15, 2005; revised March 26, 2006.

Copyright ©2006 by the American Society of Plastic Surgeons

DOI: 10.1097/01.prs.0000222582.84385.54

ANGIOSOMES OF THE FOOT AND ANKLE

Ian Taylor expanded on the work of previous anatomists¹⁻⁸ to further our understanding of muscle and skin vascular anatomy in his landmark article on angiosomes.⁹ He defined an angiosome

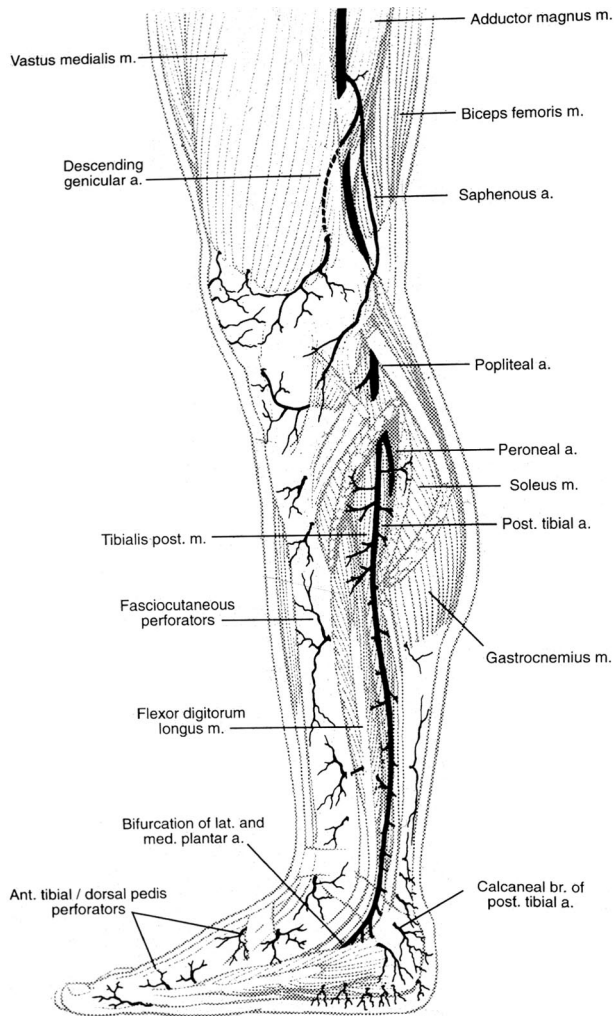


Fig. 1. The posterior tibial artery gives off perforators that arise between the flexor digitorum longus and the soleus muscle. They split into anterior and posterior branches to supply the overlying skin. Reprinted with permission from Attinger, C. Vascular anatomy of the foot and ankle. *Oper. Tech. Plast. Reconstr. Surg.* 4: 183, 1997.

as a three-dimensional anatomic unit of tissue fed by a source artery. He defined at least 40 angiosomes¹⁰ in the body, including five in the foot and ankle region. Adjacent angiosomes are bordered by choke vessels,^{11,12} which link neighboring angiosomes to one another and demarcate the border of each angiosome. In addition, these choke vessels are important safety conduits that allow a given angiosome to provide blood flow to an adjacent angiosome if the latter's source artery is damaged.

The choke vessel system links the angiosomes to one another. A unified network is created so that one source artery can provide blood flow to multiple angiosomes beyond its immediate border. Occluding or interrupting one source artery

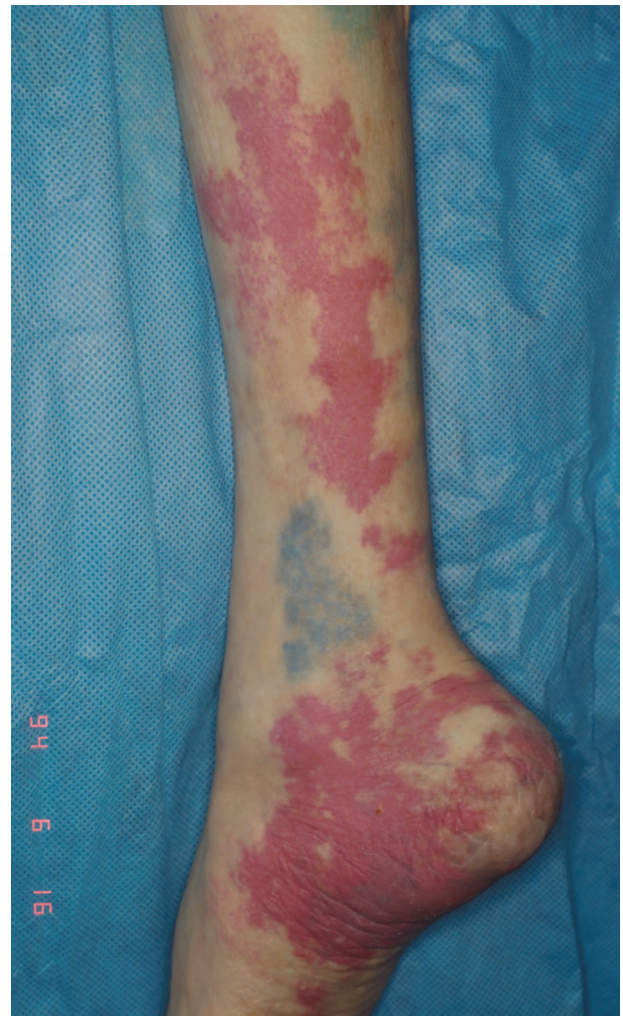

Fig. 2. This injection study shows the angiosome fed by the posterior tibial artery (salmon). The island of light blue just above the anterior medial malleolus comes from the peroneal artery via a direct arterial-arterial connection between the posterior tibial artery and the peroneal artery. Reprinted with permission from Attinger, C. Vascular anatomy of the foot and ankle. *Oper. Tech. Plast. Reconstr. Surg.* 4: 183, 1997.

surgically manipulates the system so that blood will flow through the neighboring choke vessels. This is an anatomic explanation for the "delay phenomenon."^{13,14} While the choke vessels provide an indirect connection among angiosomes, there are also direct arterial-arterial connections that allow blood flow to immediately bypass local obstructions in the vascular tree.

The six angiosomes of the foot and ankle originate from the three main arteries to the foot and ankle. The posterior tibial artery supplies the medial ankle and the plantar foot, the anterior tibial artery supplies the dorsum of the foot, and the peroneal artery supplies the anterolateral ankle

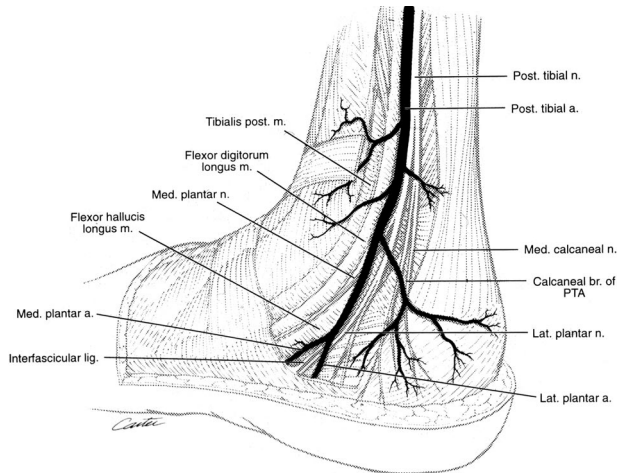


Fig.3. The medial calcaneal branch is the first main distal branch of the posterior tibial artery. Its angiosome includes the medial heel, the plantar heel, and the lateral plantar heel up to the lateral glabrous junction. Reprinted with permission from Attinger, C. Vascular anatomy of the foot and ankle. *Oper. Tech. Plast. Reconstr. Surg.* 4: 183, 1997.

and the lateral rear foot. The large angiosomes of the foot can be further broken into angiosomes of the major branches of the above arteries. The three main branches of the posterior tibial artery each supply distinct portions of the plantar foot: the calcaneal branch (heel), the medial plantar artery (instep), and the lateral plantar artery (lateral midfoot and forefoot). The two branches of the peroneal artery supply the anterolateral portion of the ankle and rear foot, the anterior perforating branch (lateral anterior upper ankle) and the calcaneal branch (plantar heel). The anterior tibial artery supplies the anterior ankle and then becomes the dorsalis pedis artery that supplies the dorsum of the foot. Detailed descriptions of the vascular anatomy¹⁵ and angiosomes of the lower leg, foot, and ankle have been thoroughly illustrated elsewhere.¹⁶⁻¹⁸

The Three Posterior Tibial Artery Angiosomes Fed by the Calcaneal, Medial Plantar, and Lateral Plantar Arteries

In the leg, the posterior tibial artery supplies the medial lower leg, starting from the anterior medial border of the tibia and extending posteriorly to the midline of the calf over the central raphe of the Achilles tendon (Figs. 1 and 2). There are smaller perforator arteries along the course of the posterior tibial artery that perforate through the flexor digitorum longus and/or soleus to supply the overlying skin. In addition, there are smaller serial branches to the deep flexor muscles,

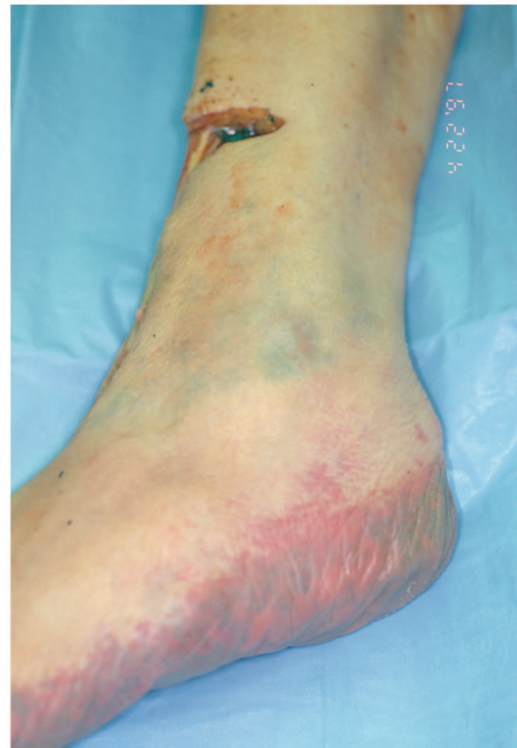
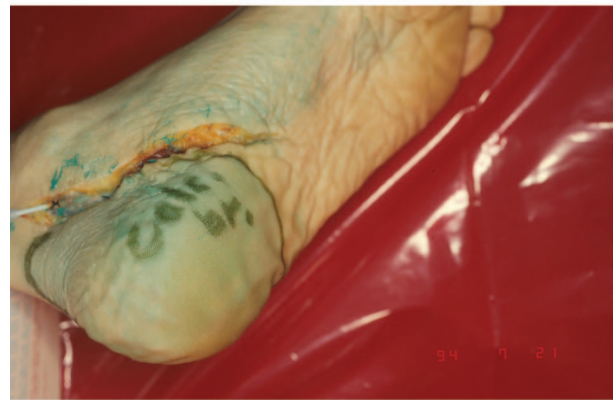
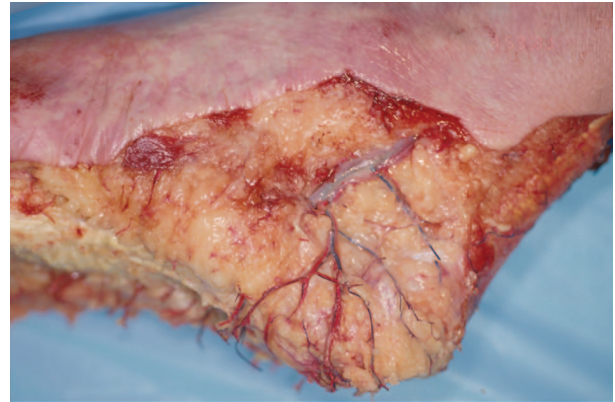Fig.4. The medial calcaneal branch is the first main distal branch of the posterior tibial artery (*above*). Its angiosome includes the medial heel (*center*), the plantar heel, and the lateral plantar heel up to the lateral glabrous junction (*below*). Reprinted with permission from Attinger, C. Vascular anatomy of the foot and ankle. *Oper. Tech. Plast. Reconstr. Surg.* 4: 183, 1997.

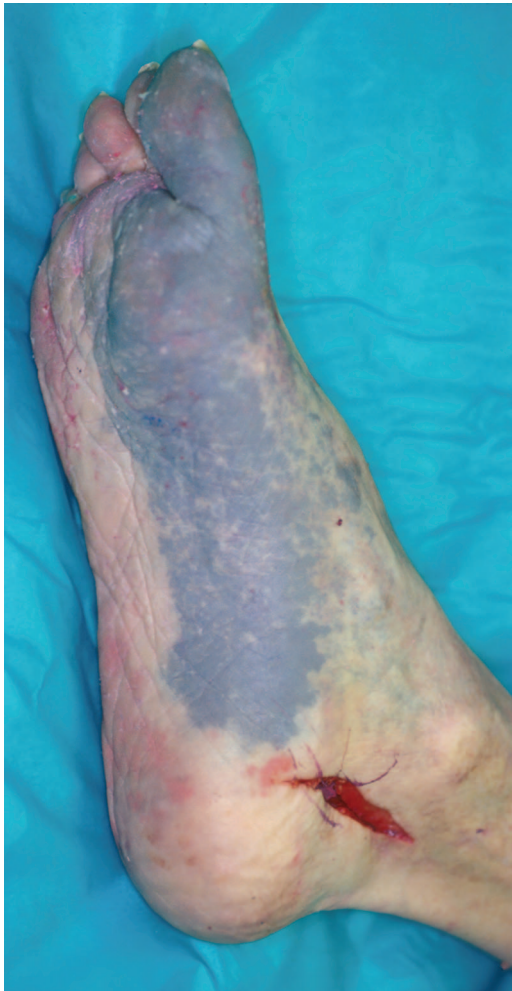

Fig. 5. The medial plantar artery's angiosome boundaries encompass the instep and, depending on anatomic variability, can include the hallux. Reprinted with permission from Attinger, C. Vascular anatomy of the foot and ankle. *Oper. Tech. Plast. Reconstr. Surg.* 4: 183, 1997.

the medial half of the soleus muscle, and the Achilles tendon.^{16,18}

In the foot, this artery gives off the posterior medial malleolar branch at the medial malleolus. The posterior medial malleolar branch joins the anterior medial malleolar branch from the dorsalis pedis artery, giving rise to an important interconnection between the posterior tibial artery and the anterior tibial artery. This system supplies the medial malleolar area. At the same level, the medial calcaneal artery branches off the posterior tibial artery inferiorly and arborizes into multiple branches that travel in a coronal direction to supply the heel. The medial calcaneal artery's angiosome boundary includes the medial and plantar heel, with its most distal boundary being the gla-

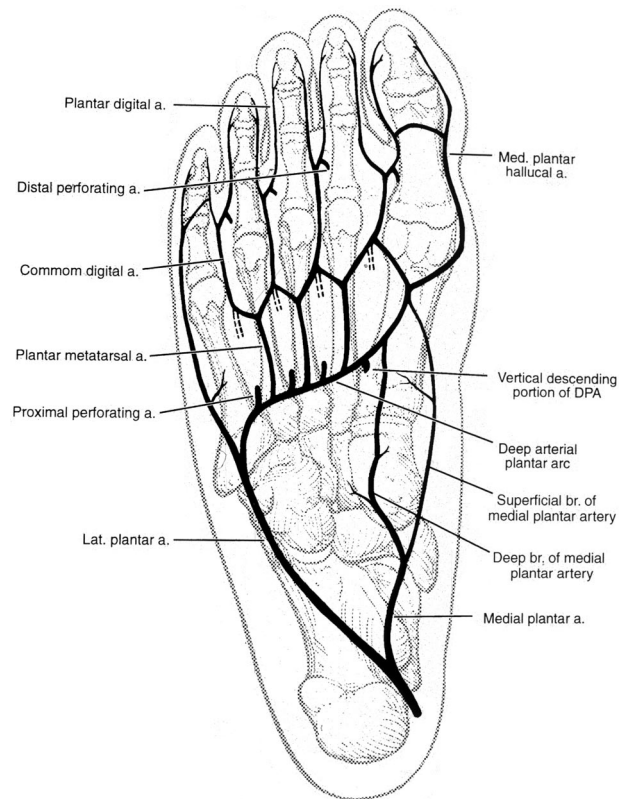


Fig. 6. The medial plantar artery gives off two main branches: the superficial branch and the deep branch. Reprinted with permission from Attinger, C. Vascular anatomy of the foot and ankle. *Oper. Tech. Plast. Reconstr. Surg.* 4: 183, 1997.

brous junction of the lateral posterior and plantar heel¹⁹ (Figs. 3 and 4).

The posterior tibial artery then enters the calcaneal canal underneath the flexor retinaculum and bifurcates into the medial and lateral plantar arteries at the level of the transverse septum, between the abductor hallucis longus and the flexor digitorum brevis muscles. The medial plantar artery's angiosome boundaries encompass the instep (Fig. 5). Its boundaries are as follows: posteriorly, the distal-medial edge of the plantar heel; laterally, the midline of the plantar midfoot; distally, the proximal edge of the plantar forefoot; and medially, an arc 2 to 3 cm above the medial glabrous junction, with its highest point being the anterior border of the navicular-cuneiform joint.

The medial plantar artery gives off two main branches, the superficial and deep branches (Figs. 6 and 7). The superficial branch of the medial plantar artery travels obliquely up to the navicular-cuneiform joint, then along the superior border of the cuneiform and the first metatarsal bone before descending to the medial plantar aspect of the distal metatarsal. Interconnections with the ante-

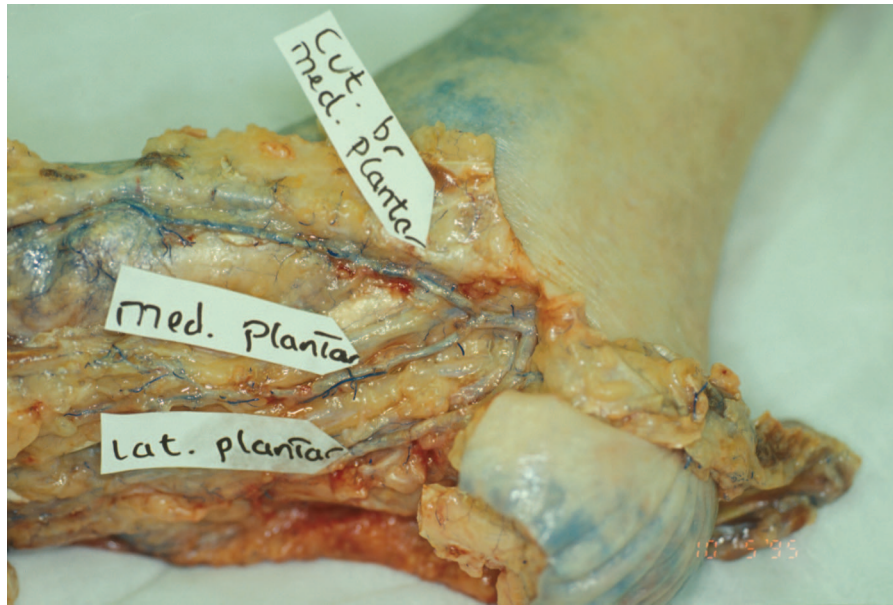


Fig. 7. The two main branches of the medial plantar artery are the superficial branch ("cut. br. medial plantar") and the deep branch ("med. plantar"). The superficial branch travels obliquely up toward the navicular-cuneiform joint and then travels along the superior border of the cuneiform and first metatarsal bone before descending to the medial plantar aspect of the distal metatarsal. The deep branch travels along the medial intramuscular septum deep and along the fibular side of the abductor hallucis muscle. Reprinted with permission from Attinger, C. Vascular anatomy of the foot and ankle. *Oper. Tech. Plast. Reconstr. Surg.* 4: 183, 1997.

rior tibial tree exist, as cutaneous branches connect proximally with medial cutaneous branches from the dorsalis pedis artery and distally with branches of the first dorsal metatarsal artery. The artery then extends plantarly and laterally, where it joins with the deep branch of the medial plantar artery and the first plantar metatarsal artery (a branch of the lateral plantar artery).

The second major branch of the medial plantar artery, the deep branch, travels deep and along the medial intramuscular septum between the abductor hallucis muscle and the flexor digitorum brevis. Perforating branches supply the medial sole of the foot. At the neck of the first metatarsal, it passes underneath the flexor tendons and anastomoses with the first plantar metatarsal artery and/or the distal lateral plantar artery.

The lateral plantar artery's angiosome includes the lateral plantar surface as well as the plantar forefoot (Fig. 8). The borders are as follows: posteriorly, the distal-lateral edge of the plantar heel; medially, the central raphe of the plantar midfoot; more distally, the glabrous junction between the medial plantar forefoot and the medial distal dorsal forefoot; and laterally, the glabrous junction between the lateral dorsum of the foot and the plantar surface of the foot (Fig.

4, below). The distal border includes the entire plantar forefoot. Note that while the hallux is usually part of the lateral plantar angiosome, it can also be part of the medial plantar artery angiosome (Fig. 5) or the dorsalis pedis angiosome (Fig. 9, right).

The lateral plantar artery enters the middle compartment of the foot, where it travels obliquely between the flexor digitorum brevis muscle and the quadratus plantar muscle toward the base of the fifth metatarsal. It then travels distal to the proximal fifth metatarsal underneath the flexor digiti minimi muscle, turns medially, forming the deep plantar arch, and crosses the proximal (two, three, and four) metatarsals. It finally anastomoses directly with the dorsalis pedis artery in the proximal first interspace (Fig. 10). This direct anastomosis between the dorsal and plantar circulation helps ensure that if either the dorsalis pedis or lateral plantar artery become occluded, flow is maintained to the entire foot.

The four plantar metatarsal arteries emanate from the deep plantar arch to nourish the plantar forefoot. They travel along each metatarsal shaft deep to the interossei and the transverse adductor muscles, but superficial to the deep transverse carpal ligament. According to Murakami, they bifur-

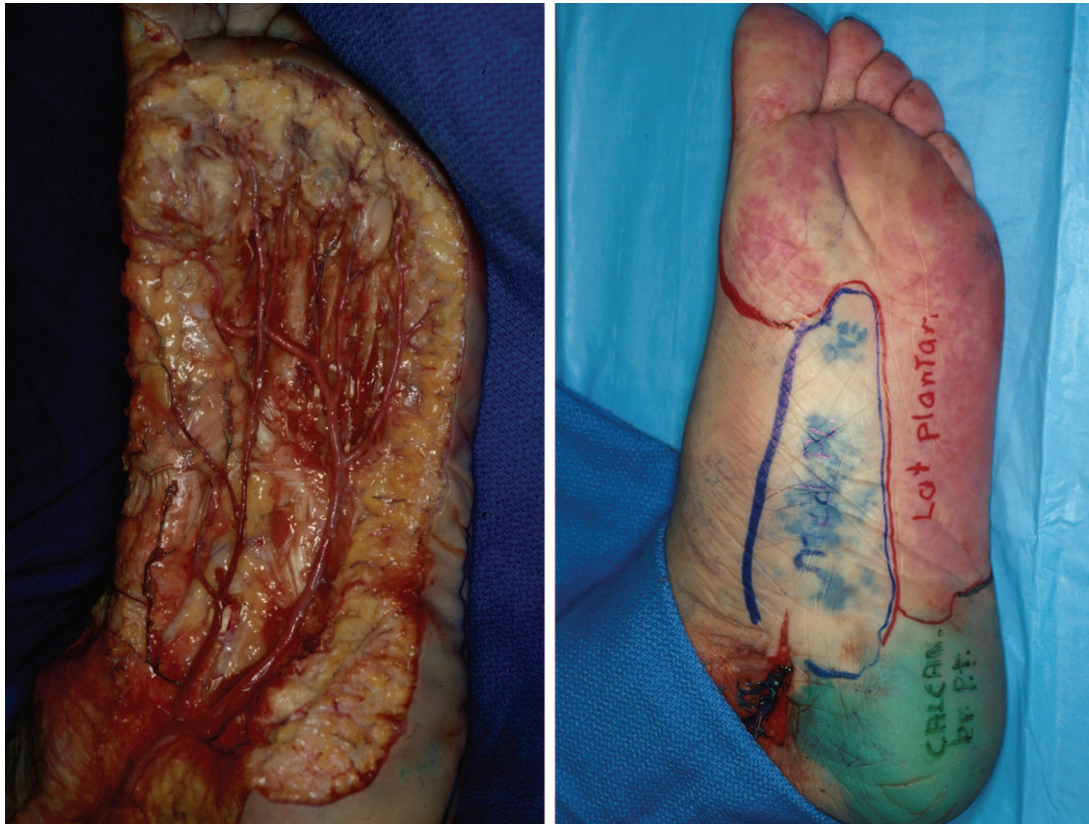

Fig. 8. The lateral plantar artery's angiosome supplies the lateral plantar surface as well as the plantar forefoot. Its posterior border is the anterior edge of the plantar heel. Its medial border in the midfoot is the central raphe of the plantar midfoot, and in the forefoot it is the glabrous juncture between the medial dorsum and plantar forefoot. Its lateral border is the glabrous juncture between the lateral dorsum of the foot and the plantar surface of the foot. The angiosome usually incorporates the hallux, although this cadaver injection demonstrates that, occasionally, the main vascular flow of the hallux can be from the dorsal circulation.

cate and are joined by the deep plantar arteries and the plantar intermetatarsal arteries to form an arcade of arterial triangles.²⁰ The common digital arteries arise at the apices of these triangles in the proximal web spaces.

The common digital arteries bifurcate into two digital arteries for each toe and are joined by distal perforating branches that originate from the dorsal metatarsal arteries. The proper plantar digital arteries are the predominant blood supply to the lesser toes, except for the medial side of the second toe, which is supplied by the first metatarsal artery (Fig. 11).²⁰

The Anterior Tibial Artery and Dorsalis Pedis Angiosome

In the leg, the anterior tibial artery's angiosome includes the area overlying the anterior compartment, with the fibula as the lateral boundary and the anterior tibia as the medial boundary (Fig. 9). This artery originates from the popliteal artery

and pierces the interosseus membrane to travel deep in the anterior compartment between the tibialis anterior muscle and extensor hallucis longus muscle. Proximally, it gives off muscle branches to supply the proximal third of the peroneus longus and brevis muscles. It then supplies the muscle of the anterior compartment via multiple small pedicles^{10–14} to the tibialis anterior muscle, extensor hallucis longus muscle, and extensor digitorum longus muscle.

At the ankle, the anterior tibial artery gives off the lateral malleolar artery at the level of the lateral malleolus that joins with the anterior perforating branch of the peroneal artery (Fig. 12). At the same level, it also gives off the medial malleolar artery, which anastomoses with the posteromedial artery of the posterior tibial artery. The anterior tibial artery then emerges under the extensor retinaculum of the ankle to become the dorsalis pedis artery. The dorsalis pedis artery's angiosome encompasses the entire dorsum of the foot (Fig.

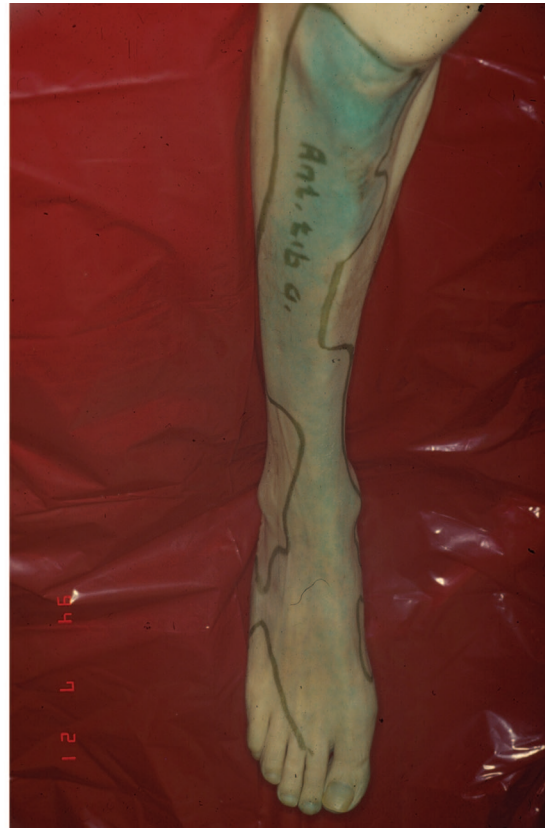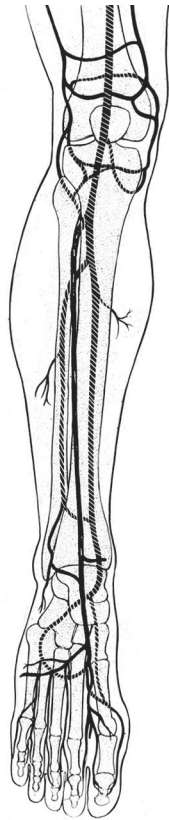


Fig. 9. The anterior tibial artery's angiosome supplies the anterior part of the leg overlying the anterior compartment, with the fibula as the lateral boundary of the anterior tibial angiosome and the anterior tibia as the medial boundary. Reprinted with permission from Attinger, C. Vascular anatomy of the foot and ankle. *Oper. Tech. Plast. Reconstr. Surg.* 4: 183, 1997.

13). This artery has arterial connections from the superficial medial plantar artery medially, from the calcaneal branch of the peroneal artery proximolaterally, and from the lateral plantar artery and its perforators distally. The dorsalis pedis artery then travels underneath the extensor hallucis longus and curves between the extensor hallucis longus and extensor digitorum longus along the dorsum of the first interspace. As Huber pointed out,²¹ the dorsalis pedis artery is absent or extremely attenuated in 12 percent of cases, and there are many anatomic variations to its course.

Typically, the dorsalis pedis artery has three lateral arterial branches, the proximal and distal tarsal arteries and the arcuate artery, and two medial branches, the medial tarsal arteries. The lateral branches are often linked together to form an interconnecting "rete" (net-like) pattern.²² The proximal lateral tarsal artery originates at the lateral talar neck. It travels underneath the extensor digitorum brevis muscle, giving off one or more branches to this muscle. Laterally, it communicates with the calcaneal branch of the peroneal artery. It may also

connect superiorly to the lateral malleolar artery and inferiorly to the arcuate artery. The third lateral branch of the dorsalis pedis, the arcuate artery, takes off at the level of the first tarsal-metatarsal joint and travels laterally over the bases of the second, third, and fourth metatarsals. It gives off the second, third, and fourth dorsal metatarsal arteries before it joins the lateral tarsal artery. Medially, the dorsalis pedis artery (usually) gives off two medial tarsal arteries. One tarsal artery is located at the middle of the navicular bone, and the other is located at the cuneonavicular joint. Usually, one of these joins with the superficial branch of the medial plantar artery.

After giving off the arcuate artery, the dorsalis pedis artery enters into the proximal first intermetatarsal space and in the process gives off the first dorsal metatarsal artery, which courses over the first dorsal interosseus muscles. The dorsalis 90-degree angle pedis artery enters that space by taking a 90-degree angle turn plantarly followed by another turn laterally to directly join with the lateral plantar artery (Fig. 10). In 22 percent of the cases²³ the first dorsal metatarsal artery originates

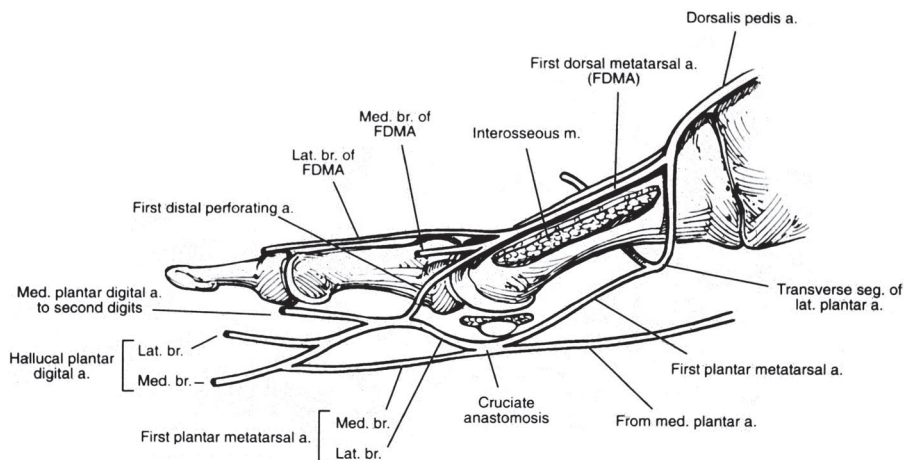
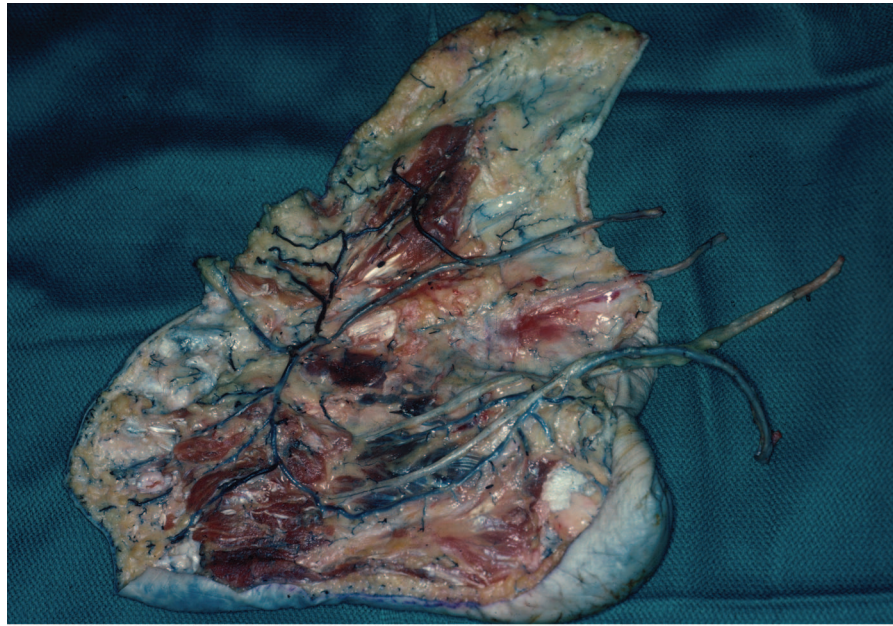


Fig. 10. (Above) In this cadaver specimen, all bones except for the calcaneus have been removed. Note the direct connection between the dorsalis pedis artery and the lateral calcaneal artery just distal to where Lisfranc's joint was. The two vessels create a U-shaped conduit that is critical in ensuring continued blood flow to the dorsum and plantar surfaces should the posterior tibial artery or anterior tibial artery become occluded. (Below) The skeletal framework shows that the dorsalis pedis artery enters into the proximal first intrametatarsal space at a 90-degree angle and then turns another 90 degrees laterally to join the lateral plantar artery. Reprinted with permission from Attinger, C. Vascular anatomy of the foot and ankle. *Oper. Tech. Plast. Reconstr. Surg.* 4: 183, 1997.

after the dorsalis pedis has made the initial downward 90-degree turn. In these instances, it rises toward the dorsum by traveling through the first interosseus muscle until it lies on top of the interosseus muscle at or near the metatarsophalangeal level. Regardless of its course, this artery is important because it supplies the first interosseus muscle, the skin overlying it, and the first web space. In addition, the first dorsal metatarsal ar-

tery distally gives off medial and lateral branches that supply blood to the hallux and second digit (Fig. 11).

The dorsal metatarsal arteries, which supply the toes, both originate from the dorsal system (the arcuate artery) and receive additional blood supply from the deep plantar system (the proximal perforating arteries) (Fig. 13, *left*). At the metatarsal heads, the dorsal metatarsal arteries

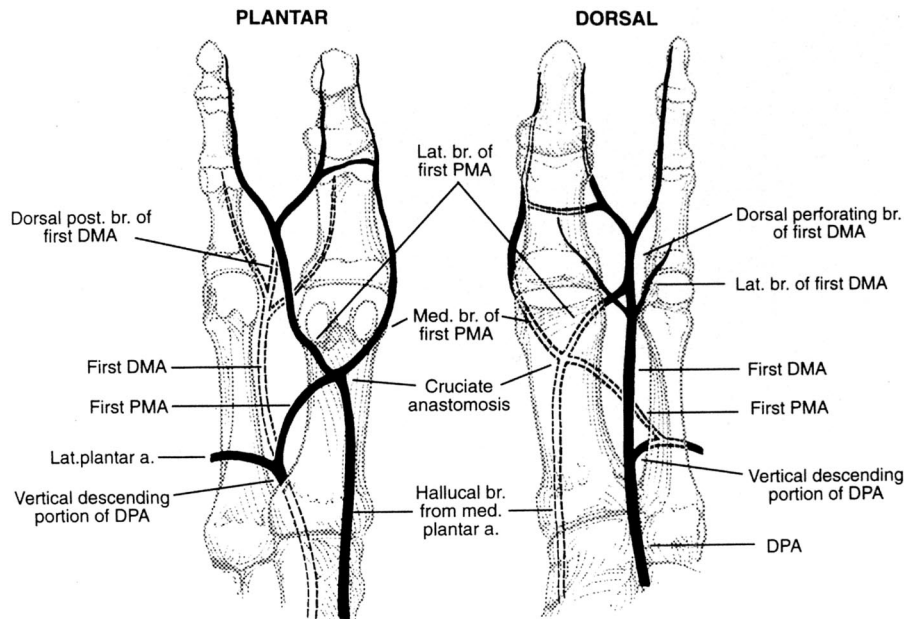


Fig. 11. The most common pattern of the first dorsal metatarsal artery and its connections with the plantar circulation is shown in dorsal and plantar views. Note the arterial-arterial connections proximally and distally in the first metatarsal interspace. Reprinted with permission from Attinger, C. Vascular anatomy of the foot and ankle. *Oper. Tech. Plast. Reconstr. Surg.* 4: 183, 1997.

divide into two dorsal digital arteries and then travel to the plantar area via the distal perforating arteries (also called anterior perforating arteries). These perforating arteries join the plantar metatarsal artery to supply the plantar digits. In this way, the web space and the toes on either side of the web space receive dorsal and plantar blood supply from a dual system: the dorsalis pedis artery and the lateral plantar artery.

Angiosomes from the Peroneal Artery Fed by the Calcaneal Branch and Anterior Perforating Branches

The peroneal artery arises from the tibial peroneal trunk and courses along the medial side of the fibula, supplying the posterolateral lower leg, ankle, and heel (Fig. 14). The peroneal artery angiosome is bounded laterally by the central raphe overlying the Achilles tendon and medially by the anterior edge of the lateral compartment (Fig. 15). It supplies the muscles in the deep posterior compartment muscles (tibialis posterior, flexor hallucis longus, flexor digitorum longus), the fibula, the lower lateral portion of the soleus muscle, the lateral half of the Achilles tendon, and the lower distal two-thirds of the peroneus longus and brevis muscles. The posterior lateral skin of the leg is supplied by peroneal perforators (at 3- to 5-cm

intervals) that travel close to, along, or through the posterolateral intramuscular septum.^{24,25}

Before the peroneal artery emerges at the level of the lateral malleolus, it bifurcates (forming a delta) into the anterior perforating branch and the lateral calcaneal branch (Fig. 16). The lateral calcaneal branch's angiosome includes the plantar and lateral heel (Fig. 17, *left*). More specifically, the proximal boundaries extend medially to the medial glabrous junction of the heel, distally to the proximal fifth metatarsal, and superiorly to the lateral malleolus. The course of the lateral calcaneal artery begins at the level of the lateral malleolus as it emerges laterally between the Achilles tendon and the peroneal tendons. It curves with peroneal tendons 2 cm distal to the lateral malleolus and gives rise to four or five small calcaneal branches.¹⁹ The lateral calcaneal artery terminates at the level of the fifth metatarsal tuberosity, where it connects with the lateral tarsal artery. Note that the heel is privileged in that it has two overlapping source arteries: the medial and lateral calcaneal arteries (Fig. 17, *center* and *right*). This ensures duplicate blood supply to an area regularly traumatized during ambulation.

The anterior perforating branch's angiosome overlies the distal interosseus membrane and extends over the anterolateral ankle. The anterior branch

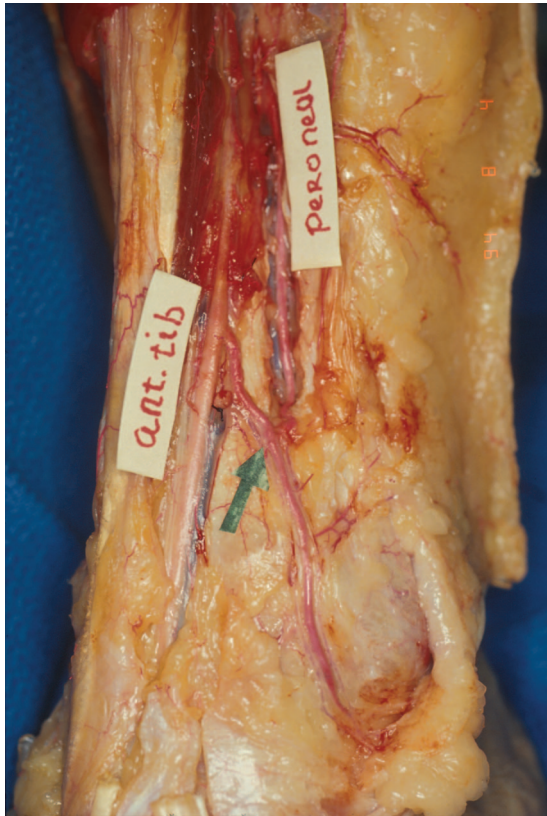


Fig. 12. At the ankle, the anterior tibial artery gives off the lateral malleolar artery at the level of the lateral malleolus. It anastomoses with the anterior perforating branch of the peroneal artery. Reprinted with permission from Attinger, C. Vascular anatomy of the foot and ankle. *Oper. Tech. Plast. Reconstr. Surg.* 4: 183, 1997.

pierces through the anterior intermuscular septum and sends a branch superiorly overlying the intermuscular septum (this area encompasses the area from which the supramalleolar flap²⁶ can be harvested). The anterior perforating artery then connects directly with the anterior lateral malleolar artery (Fig. 12).

ANATOMIC AND CLINICAL EVALUATION OF ARTERIAL-ARTERIAL CONNECTIONS

Arterial-arterial connections allow for uninterrupted blood flow to the entire foot despite the occlusion of one or more arteries. By understanding the location of these arterial connections in the foot and ankle, the surgeon can determine both the presence of flow from the source artery and determine which artery is predominately supplying a given angiosome (Figs. 18 and 19 and Table 1). The use of the handheld Doppler instrument at the specific anatomic locations described above (or in any anatomic

text) can give a very accurate description of existing blood flow.²⁷

After locating the artery with the Doppler, the direction of flow can be evaluated by applying selective occlusion with finger pressure above and below the area being studied. The initial character of the Doppler signal helps to evaluate the quality of flow present in the artery. Triphasic flow indicates normal arterial flow. Biphasic flow indicates mildly compromised flow. Monophasic flow indicates arterial compromise, unless the patient suffers from sympathetic neuropathy (a common complication of diabetes) and the distal vessels have lost their tone. A blunt, short, monophasic spitting sound indicates complete distal occlusion with no runoff.

For example, it should be straightforward to determine whether the flow to the dorsum of the foot is derived from the anterior tibial artery, the peroneal artery (via the anterior perforating branch), or the posterior tibial artery (via the lateral plantar artery) by listening and selectively occluding these areas. In addition, one should be able to determine whether the blood flow to the heel is coming directly from the calcaneal branch of the posterior tibial artery, the calcaneal branch of the peroneal artery, or indirectly from the anterior tibial artery via the lateral malleolar branch. Incidentally, this directional flow assessment and arterial predominance provide additional information to that obtained by routine angiography.

In the patient with diabetes mellitus and/or peripheral vascular disease who presents with a foot ulcer or rest pain, this clinical assessment can aid enormously in choosing which incisions to make if the patient requires a débridement or closure. In these patients it is crucial that the critically redirected blood flow is not compromised by a poorly planned surgical incision. Moreover, this directional assessment aids the vascular surgeon in ensuring that the bypass will actually reach the angiosome that is ischemic. It has been reported that 15 percent of bypasses fail to heal the foot despite remaining patent, because the bypass failed to revascularize the affected angiosome.²⁸

Arterial-Arterial Connections around the Ankle

Arterial connections around the ankle are complex and difficult to evaluate. All three main arteries of the leg communicate with each other around the ankle. The peroneal artery communicates with the anterior tibial artery via the anterior perforating branch and the lateral malleolar branch, and the peroneal and posterior tibial arteries share three transverse communi-

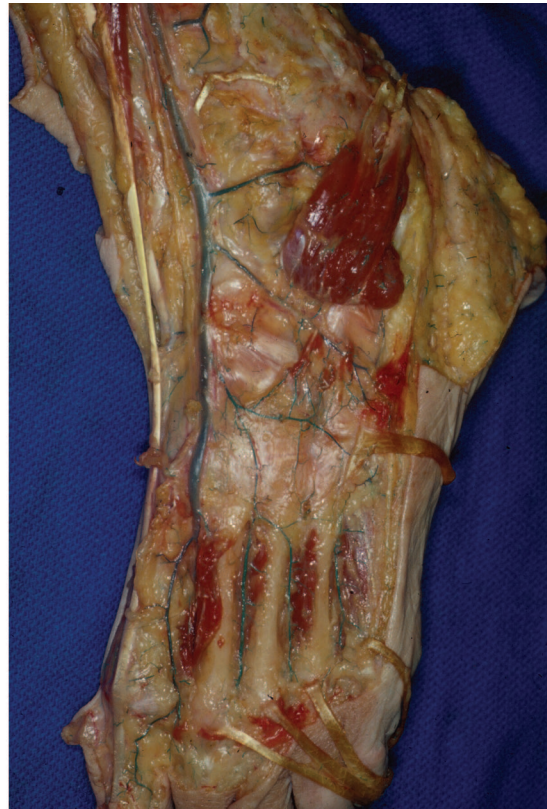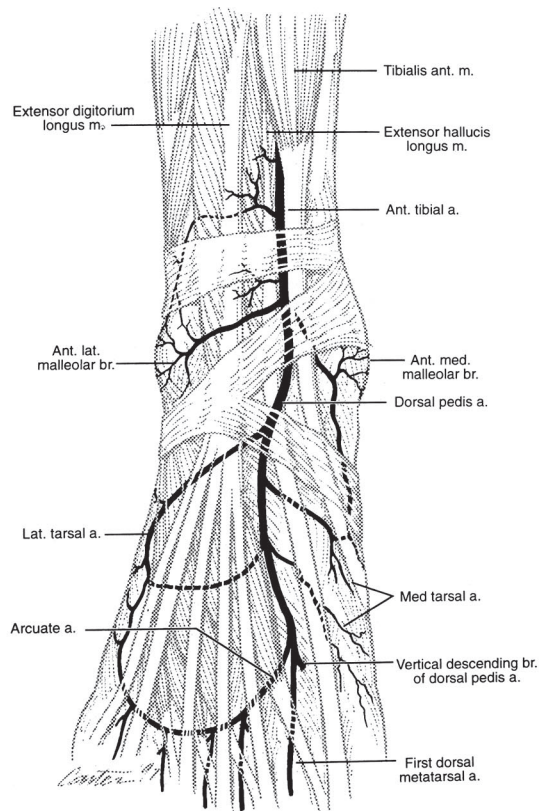


Fig. 13. The dorsalis pedis artery angiosome supplies the entire dorsum of the foot, although it gets contributions medially from the superficial medial plantar artery, anteriorly from the perforators of the lateral plantar artery, and laterally from both the calcaneal and anterior perforating branches of the peroneal artery. (Right) In this anatomic dissection, the arcuate artery is vestigial at best and the dorsal metatarsal arteries are getting their main blood supply from the lateral plantar artery via proximal perforators.

cating branches. The anterior tibial and posterior tibial arteries communicate directly via the anastomoses of the dorsalis pedis with the lateral plantar arteries.

Anterior Tibial and Peroneal Connections

The anterior tibial and peroneal arteries are directly connected through the anterior perforating branch of the peroneal artery and the lateral malleolar branch of the anterior tibial artery (Fig. 12); thus, the flow of the peroneal artery can be retrograde from the anterior tibial artery via the lateral malleolar artery or antegrade where it supplies the anterior tibial artery.

To evaluate the direction of flow at the peroneal artery, perform a Doppler examination of the anterior perforating branch of the peroneal artery (Fig. 20), which is usually found in the soft area just above the ankle joint between the tibia and the fibula. Next, occlude the anterior tibial artery at the takeoff of the lateral malleolar branch. If the Doppler sounds continue, there is antegrade flow along the anterior perforating branch of the peroneal artery. However, if the Doppler sound stops,

then there is no antegrade flow and the distal peroneal artery depends on the anterior tibial artery via the lateral malleolar artery for retrograde flow. Disruption of that connection can put the lateral ankle soft tissue in jeopardy.

To assess whether the peroneal artery is contributing significantly to the anterior tibial artery flow, the anterior perforating branch is occluded while the Doppler device is placed on the anterior tibial artery. Because of possible retrograde flow from the posterior tibial artery via the dorsalis pedis artery, it is important to also occlude the anterior tibial artery distal to the takeoff of the lateral malleolar artery. If there is no Doppler sound, then the pressure over the anterior perforating branch is lifted. If flow returns, then the anterior tibial artery and dorsalis pedis arteries receive their blood flow in part (or in total) from the peroneal artery.

Peroneal and Posterior Tibial Connections

The peroneal artery communicates distally with the posterior tibial artery via one to three transverse communicating branches that are lo-

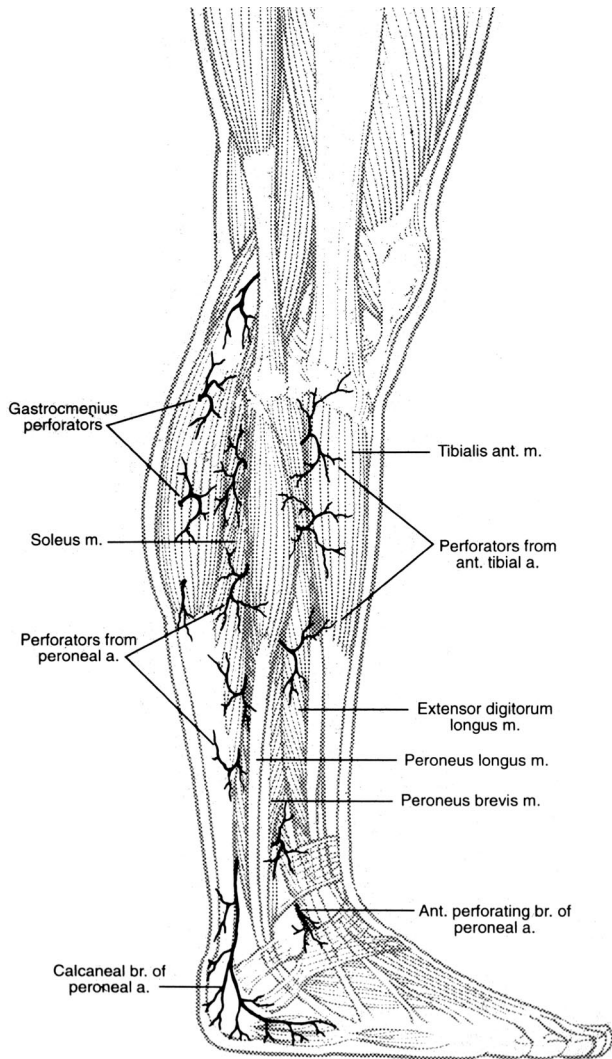


Fig. 14. The peroneal artery branches off the tibial peroneal trunk to travel along the medial side of the fibula in the deep compartment and supply the posterolateral lower leg, ankle, and heel. Perforators (at 3- to 5-cm intervals) travel close to, along, or through the posterolateral intramuscular septum before supplying the posterolateral skin.

cated within the fat pad deep to the Achilles tendon (Fig. 21). These branches are located 5 to 7 cm above the ankle joint, at the ankle joint, and just above the insertion of the Achilles tendon. Because of these connections, it is impossible by Doppler imaging to know whether the flow along the distal posterior tibial artery originates directly from the proximal posterior tibial artery or indirectly from the distal peroneal artery via the above perforators. Likewise, one cannot tell whether the flow along the peroneal artery originates from the peroneal artery or from the posterior tibial artery via those same perforators.¹⁸

Anterior Tibial and Posterior Tibial Connections

The anterior tibial artery and posterior tibial artery are also directly connected distal to Lisfranc's joint, where the dorsalis pedis artery enters into the proximal first interspace to join directly with the lateral plantar artery (see Fig. 10). To evaluate whether the flow along the anterior tibial artery is antegrade or retrograde (Fig. 22), place the Doppler probe over the anterior tibial artery and occlude the more distal dorsalis pedis artery. It is also important to occlude the lateral malleolar artery at the same time, to avoid contributions from the peroneal artery (Fig. 12). If the signal persists despite occlusion, there is antegrade flow. However, if the sound disappears, the flow along the anterior tibial artery is retrograde from either the peroneal artery or from the posterior tibial artery via the lateral plantar and dorsalis pedis arteries. In this instance, interruption of these connections could lead to anterior compartment ischemia or tissue loss.

To assess the direction and character of flow of the posterior tibial artery, the Doppler probe is placed over the artery at the tarsal tunnel. The posterior tibial artery can be occluded distally (Fig. 23), and if the signal remains, there is antegrade flow along the posterior tibial artery. If there is no signal with the distal occlusion, the flow is retrograde from the anterior tibial artery via the dorsalis pedis and lateral plantar arteries. No antegrade flow along the posterior tibial artery suggests significant vascular disease in that not only is the posterior tibial artery occluded but the peroneal artery is probably also occluded because of the arterial connections discussed above. This is the scenario frequently seen in heel decubitus ulcers in the elderly.

As we have previously shown, the importance of evaluating the patency of the distal connection between the anterior and posterior tibial arteries cannot be emphasized enough. If that connection is critical to supplying either the dorsal or plantar surface of the foot because of existing obstruction of one of the two arteries, damaging that connection while performing an operation or amputation can lead to gangrene on the portion of the foot that was dependent on retrograde flow (Fig. 24).¹⁸

Arterial-Arterial Connections around the Heel

The heel is unique in that it is the only angiosome that receives inflow from two source ar-

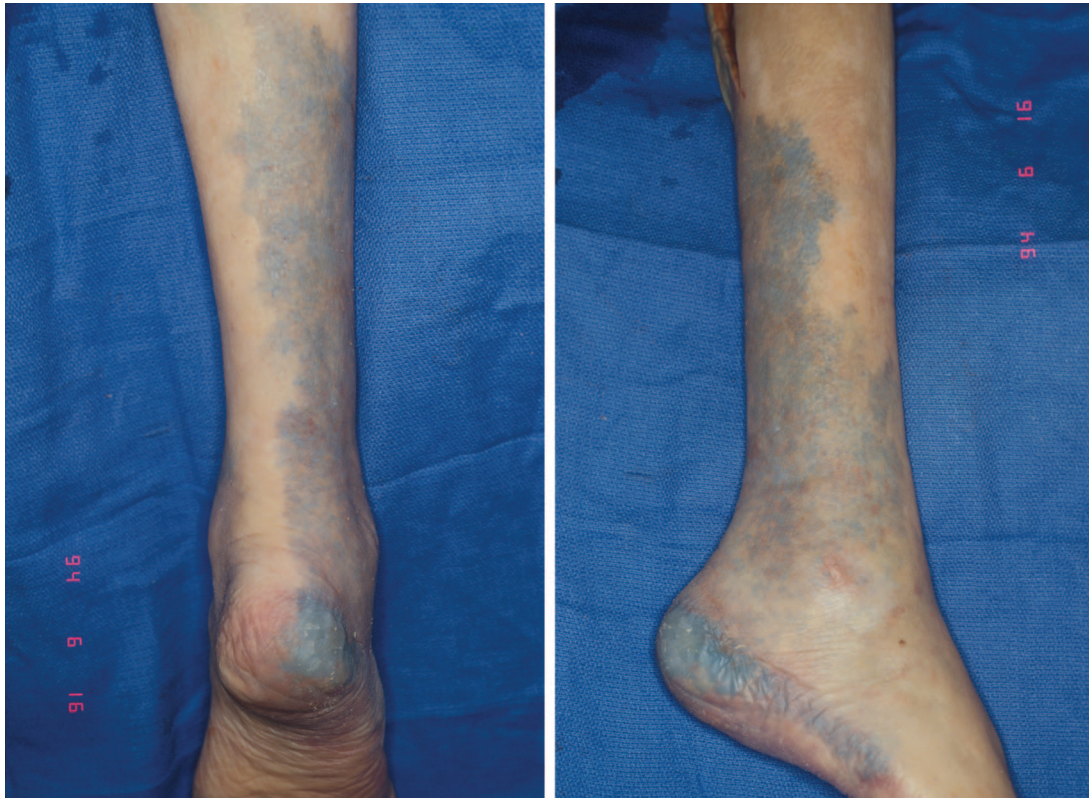


Fig. 15. The peroneal artery's angiosome extends from the midline of the posterior calf (*left*) to the anterior edge of the lateral compartment (*right*). It extends inferiorly to the anterolateral ankle and lateral heel. Reprinted with permission from Attinger, C. Vascular anatomy of the foot and ankle. *Oper. Tech. Plast. Reconstr. Surg.* 4: 183, 1997.

teries: the calcaneal branch of the posterior tibial artery and the calcaneal branch of the peroneal artery (Fig. 17, *right*). The posterior tibial calcaneal branch supplies the medial aspect of the heel, while the peroneal calcaneal branch supplies the lateral aspect of the heel. The former runs directly toward the heel pad along the center of the medial heel, while the latter curves around the lateral malleolus 2 cm distal to the malleolar tip and travels to the proximal fifth metatarsal head. There are no anatomic arterial-arterial connections between these arteries; therefore, a Doppler signal obtained in this location represents only antegrade flow. However, it is important to assess the flow in both the calcaneal branch of the posterior tibial artery and the peroneal artery (Fig. 25), to determine whether one artery predominates over the other. This becomes relevant when one is planning to perform a midline Gaenslen incision to expose the plantar calcaneus.²⁹

Arterial-Arterial Connections of the Plantar Foot

There are multiple levels of arterial-arterial interconnections in the plantar foot. Proximally

and medially, there are the connections between the branches of the medial tarsal artery and the superficial medial plantar artery, but the medial tarsal artery is often too small to accurately examine using the Doppler device. At Lisfranc's joint, the dorsal circulation and plantar circulation are linked together via proximal perforators. Medially, the dorsalis pedis links directly with the lateral plantar artery (Fig. 10). More laterally, the dorsal and plantar metatarsal arteries are linked at their takeoff by the proximal perforating branches (Fig. 13, *left*). At the web spaces, distal perforating arteries again link the dorsal and plantar metatarsal arteries. The final arterial-arterial interconnection is a fine subdermal arteriolar plexus linking the dorsalis pedis with the lateral plantar artery in a circumferential wraparound pattern about the plantar foot.

Dorsalis Pedis and Lateral Plantar Arteries

In the plantar foot, the principle connection to evaluate is that between the dorsalis pedis and lateral plantar arteries. First, use the Doppler device to examine the lateral plantar artery proximal to the base of the proximal first interspace (Fig. 26). Then, occlude the dorsalis pedis at the tarsal-

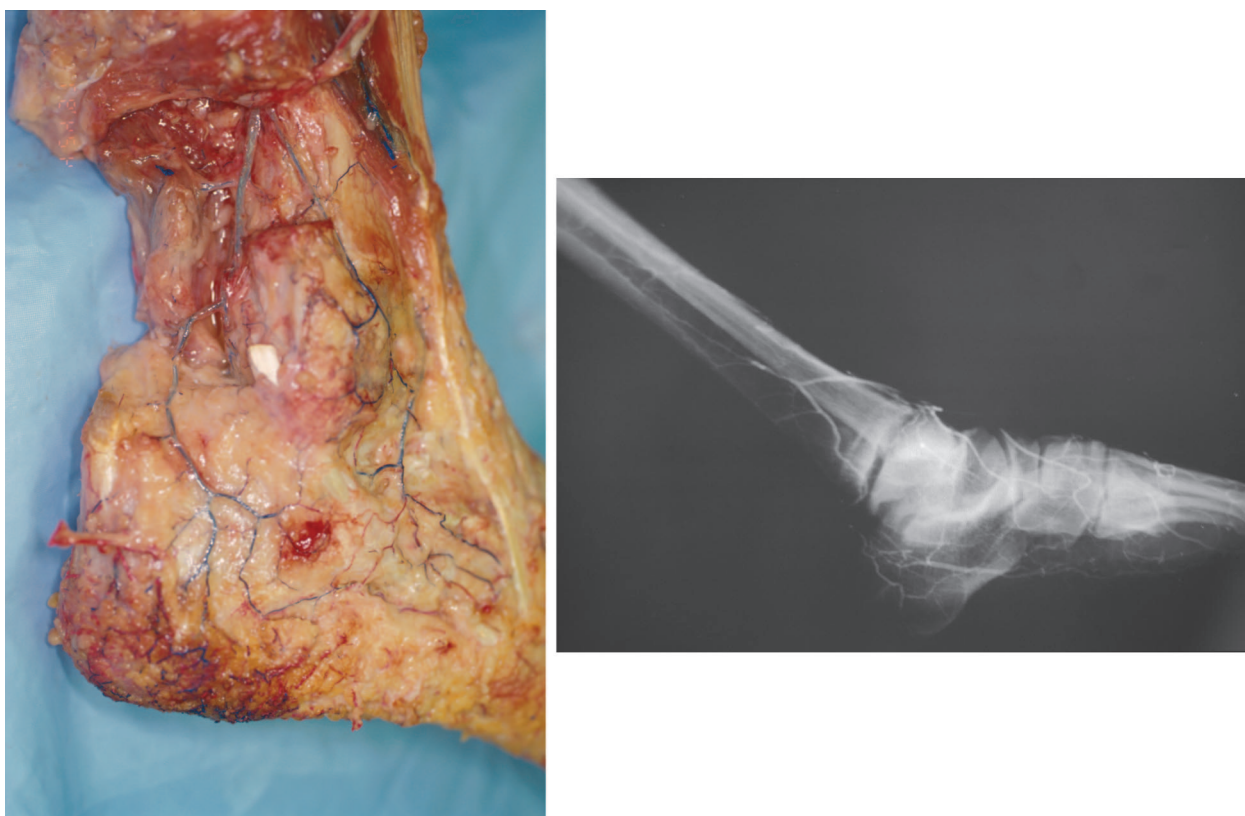


Fig. 16. Before the peroneal artery emerges at the level of the lateral malleolus, it bifurcates into the anterior perforating branch and the lateral calcaneal branch. (*Left*) The cadaver dissection shows the bifurcation after the fibula was removed. (*Right*) Angiogram view of the same bifurcation.

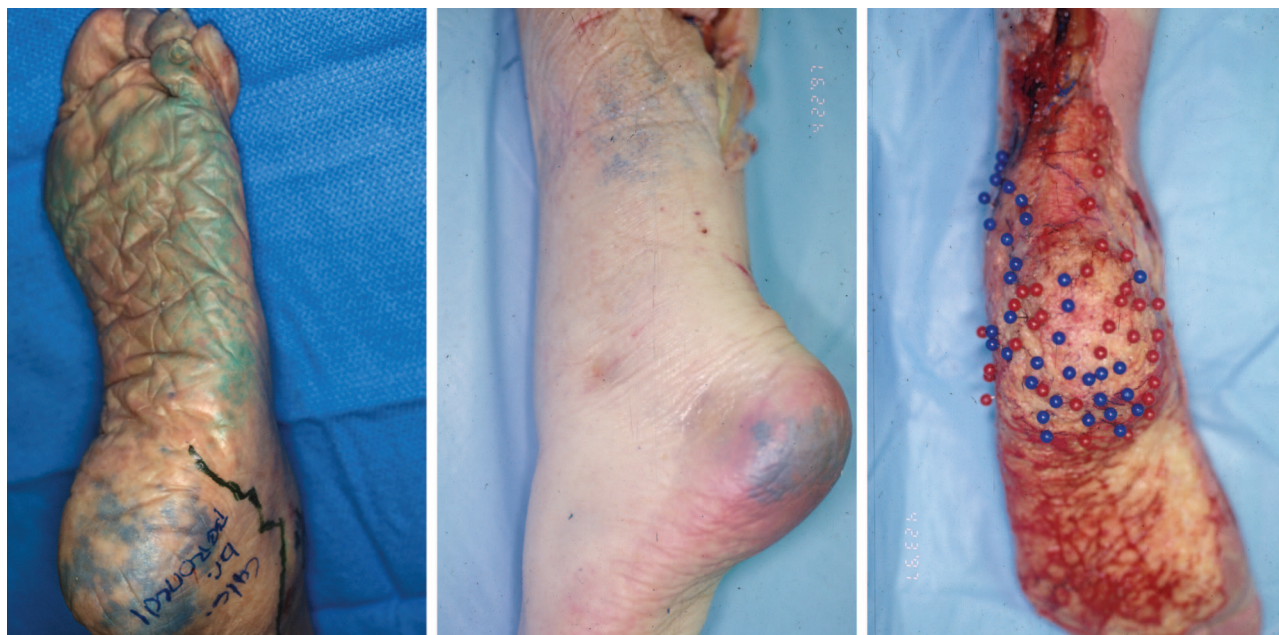


Fig. 17. The calcaneal branch of the peroneal artery supplies the entire plantar heel as well as the lateral ankle (*left*). Note that the heel is privileged in that it has two source arteries: the medial (*salmon*) and lateral (*blue*) calcaneal arteries. The overlap is best shown in this cadaver specimen (*center*), where each branch was injected with a different color and they completely overlap. The skin was then removed and the different colored perforators were marked with different colored pins, further emphasizing the overlap (*right*).

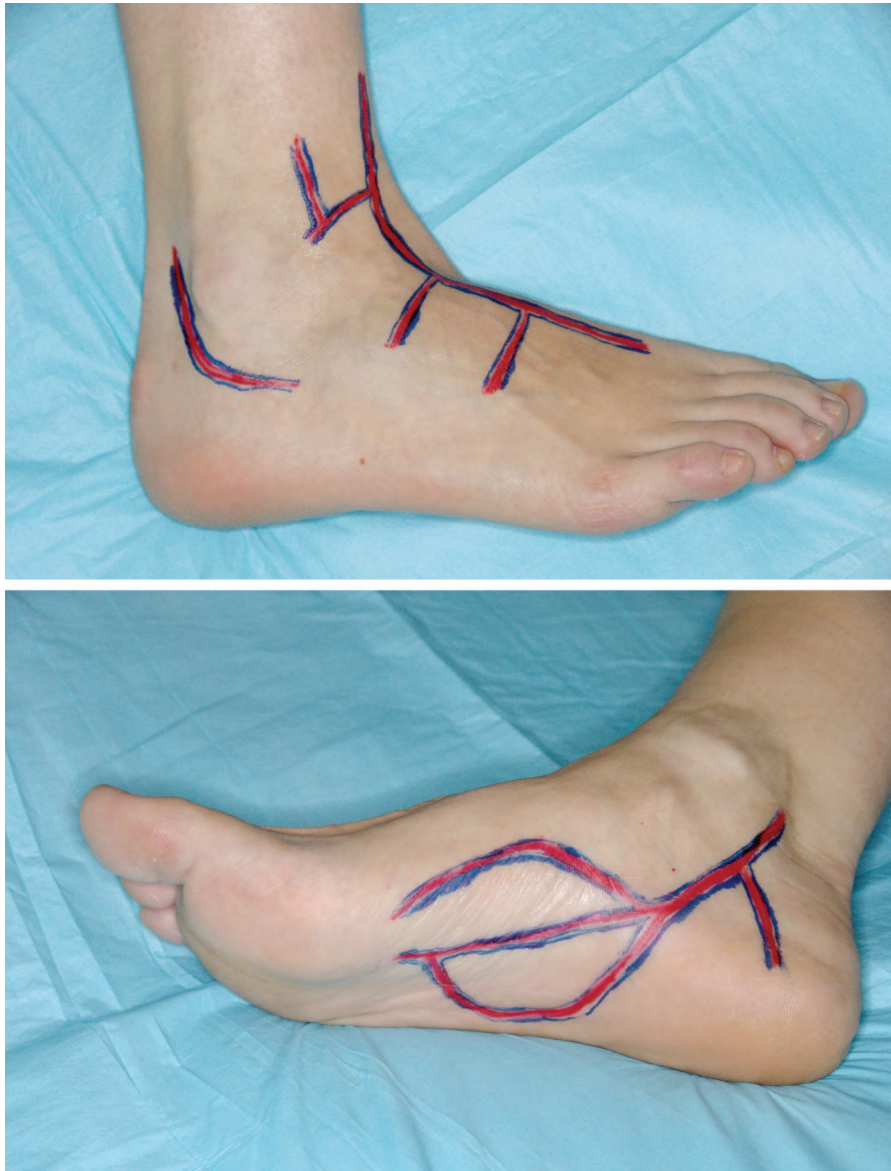


Fig. 18. The topical locations of the underlying vascular anatomy of the ankle and the dorsal and plantar foot are shown. By using this anatomic outline and the Doppler device, one can accurately predict the existing vascular flow to the foot.

metatarsal joint. If the signal disappears, then flow in the lateral plantar artery depends on the dorsalis pedis arterial flow. However, if the sound remains, it means that there is antegrade flow from the posterior tibialis artery to the lateral plantar artery. In rare circumstances, the presence of a signal over the lateral plantar artery with an occluded dorsalis pedis artery could represent a proximally occluded lateral plantar artery getting retrograde flow from the medial plantar artery via the cruciate anastomosis (Fig. 11).

Connections at the Cruciate Anastomosis

A second source of arterial-arterial anastomosis occurs proximal to the first metatarsal head at

the cruciate anastomosis, where the superficial and deep medial plantar arteries join (Fig. 11). The distal lateral plantar artery also joins the cruciate anastomosis, linking the medial plantar artery with the lateral plantar artery. The blood supply to the first toe depends on which arteries anastomose and which provide the major blood supply to the cruciate anastomosis—the medial plantar artery, lateral plantar artery, or first dorsal metatarsal artery (Fig. 27).

To determine the flow at the cruciate anastomosis, use the Doppler device to study the deep medial plantar artery proximally (Fig. 28). Then, apply pressure at the cruciate anastomosis just

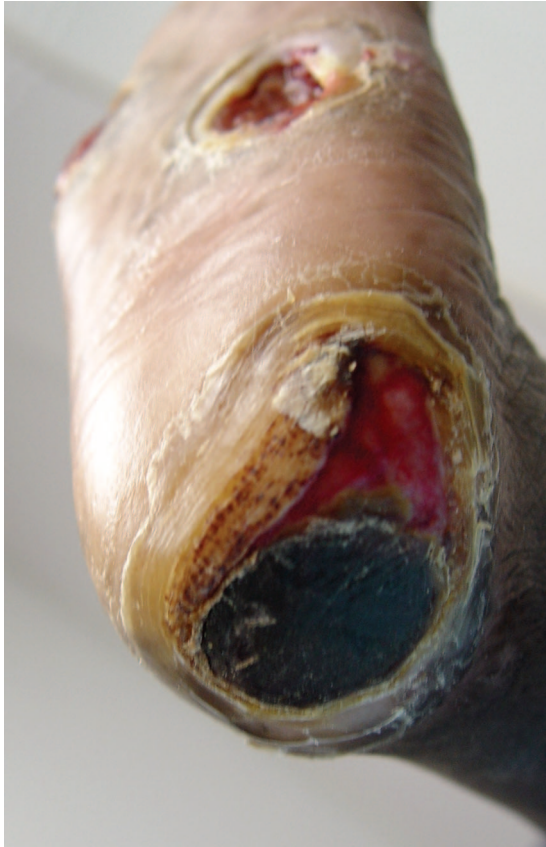

Fig. 19. In this patient with a heel ulcer, there was a triphasic sound over the dorsalis pedis in an antegrade direction and no retrograde flow. The opposite was true for the posterior tibial artery, where there is no antegrade flow but strong biphasic retrograde flow. This signifies that the flow to the plantar foot and heel comes from the dorsalis pedis artery. The peroneal artery contributes little, with only monophasic antegrade flow. Any reconstructive option considered has to preserve the dorsal to plantar vascular connections so as not to render the plantar surface ischemic (Table 1).

Table 1. Doppler Examination

Artery	Antegrade Flow	Retrograde Flow
Peroneal	Monophasic	—
Dorsalis pedis	Triphasic	—
Posterior tibial	—	Biphasic

proximal to the first metatarsal head and at the proximal lateral plantar artery simultaneously. If the signal persists, then there is antegrade flow along the deep medial plantar artery. If it disappears, then the flow is retrograde. To determine whether the dorsalis pedis or the lateral plantar artery provides the retrograde flow, occlude the medial plantar arteries at their takeoff and then selectively occlude and release the dorsalis pedis

artery and the lateral plantar artery, respectively. Further selective occlusion and release of the superficial medial plantar branch, the dorsalis pedis, the deep medial plantar branch, and the lateral plantar branch can accurately establish the exact flow pattern at the cruciate anastomosis.

Dorsalis Pedis and Lateral Plantar Arteries Linked by the Subdermal Plexus

The final arterial-arterial interconnection was first described by Hidalgo and Shaw,³⁰ who showed a fine subdermal arteriolar plexus linking the dorsalis pedis with the lateral plantar artery in a circumferential wraparound pattern about the plantar foot (Fig. 29). These arteries are of extremely fine caliber (0.1 to 0.2 mm) and are too small to assess with the Doppler probe. They span the angiosome boundaries of the dorsalis pedis artery, medial plantar artery, and lateral plantar artery. Because their presence has not masked the defined boundaries of the plantar angiosomes, it is thought that this subdermal circulation provides an additional but limited source of blood flow. However, this circulation undoubtedly plays a role in allowing the sole to recover from the daily trauma of walking or if there is damage to the principle blood supply.

Connections on the Dorsum of the Foot

As discussed above, the dorsal and plantar arterial systems are closely linked at multiple levels. The most proximal is located in the medial foot, where the medial tarsal artery communicates with the superficial (medial branch) of the medial plantar artery. It is usually too difficult to use Doppler imaging on this small connection. Laterally, there is the “rete” (net) that connects the proximal lateral tarsal artery, the distal tarsal and arcuate arteries, and the lateral malleolar artery and the anterior perforating branch of the peroneal superiorly. In addition, the calcaneal branch of the peroneal artery connects with the lateral tarsal artery.

Because of this complex network of connections, it is very difficult to determine the source of retrograde flow over the major tarsal artery when it is occluded proximally. If there is retrograde flow along the proximal lateral tarsal artery, it signifies an intact network of connections that can include the anterior perforating branch of the lateral plantar artery, the lateral malleolar artery, the calcaneal branch of the peroneal artery, the distal tarsal artery arcuate artery, and the arcuate artery.

Another important arterial connection that has been described above occurs just distal to Lis-

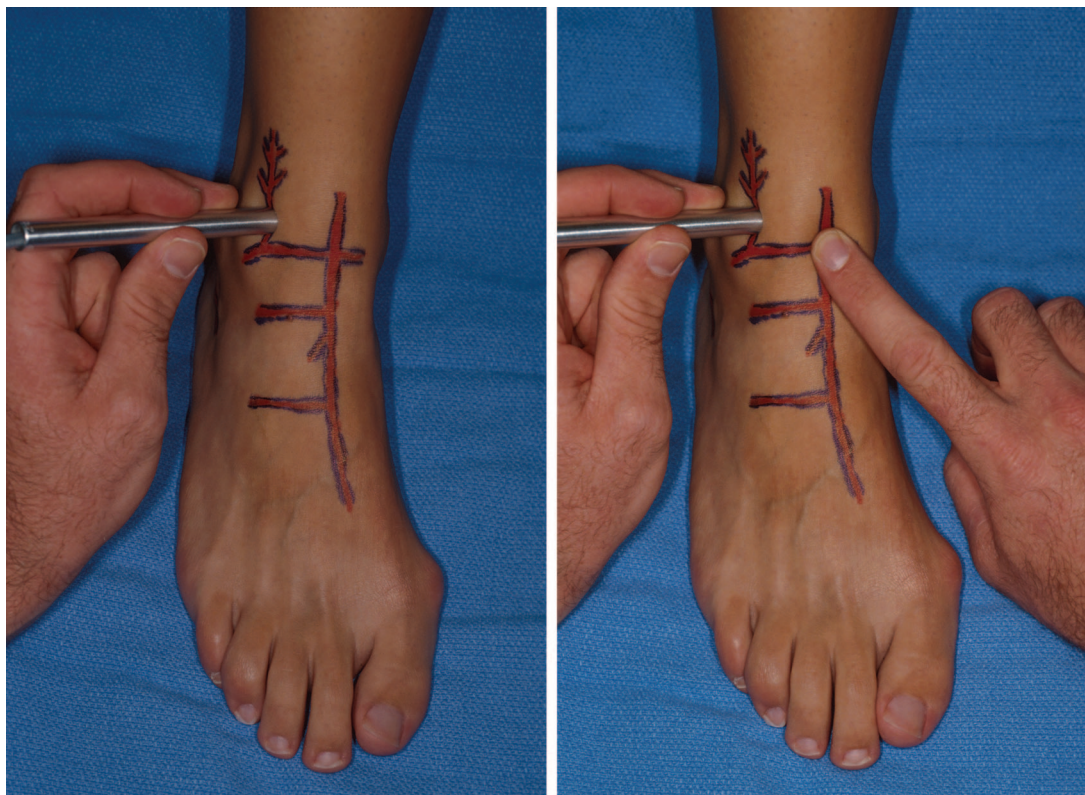


Fig. 20. The anterior perforating branch of the peroneal artery is located in the lateral soft area just above the ankle joint between the tibia and the fibula (*left*). Then, the anterior tibial artery is occluded at the takeoff of the lateral malleolar branch (*right*). If the Doppler sounds continue, then there is antegrade flow along the anterior perforating branch of the peroneal artery.

franc's joint, where the dorsalis pedis artery joins the lateral plantar artery in the proximal first interspace (Fig. 10). To determine the direction of flow, the dorsalis pedis is examined by Doppler proximal to Lisfranc's joint. If pressure is applied to the posterior tibial artery at the tarsal tunnel and the Doppler sound continues, then there is antegrade flow. If the Doppler sound disappears, then the flow to the dorsalis pedis artery is retrograde from the posterior tibial artery via the lateral plantar artery (Fig. 30). At the proximal metatarsal interspaces and at distal web spaces, the proximal and distal perforating arteries, respectively, link the dorsal and plantar metatarsal arteries (Fig. 13, *left*). The direction(s) of flow along the dorsal metatarsals can be easily determined. By using the Doppler device on the artery proximally and occluding distally, one can establish whether there is antegrade flow. By using the Doppler device on the artery distally and occluding proximally, one can establish whether retrograde flow is present. This also establishes the patency of the distal perforators in the web space (Fig. 31). This close linkage ensures that collateral flow will compen-

sate for occlusions to either the dorsalis pedis or posterior tibial artery.

USING THE PRINCIPLES OF ANGIOSOMES TO MAKE SAFE INCISIONS IN NORMAL AND VASCULARLY COMPROMISED PATIENTS

As we have previously reported in far more detail, there are four important factors to be considered and balanced when choosing where to place an incision.¹⁸ Of course, the incision must provide adequate exposure for the planned procedure. In addition, there must be adequate blood supply on either side of the incision to optimize healing. Third, the incision should spare the sensory and motor nerves. Finally, the incision should not be placed perpendicular to a joint, because of the risk of causing scar contracture and resultant joint immobility. Although adequate exposure, nerve location, and scar contracture are important factors, we will focus primarily on the vascular ramifications of typical incisions in the foot and ankle.

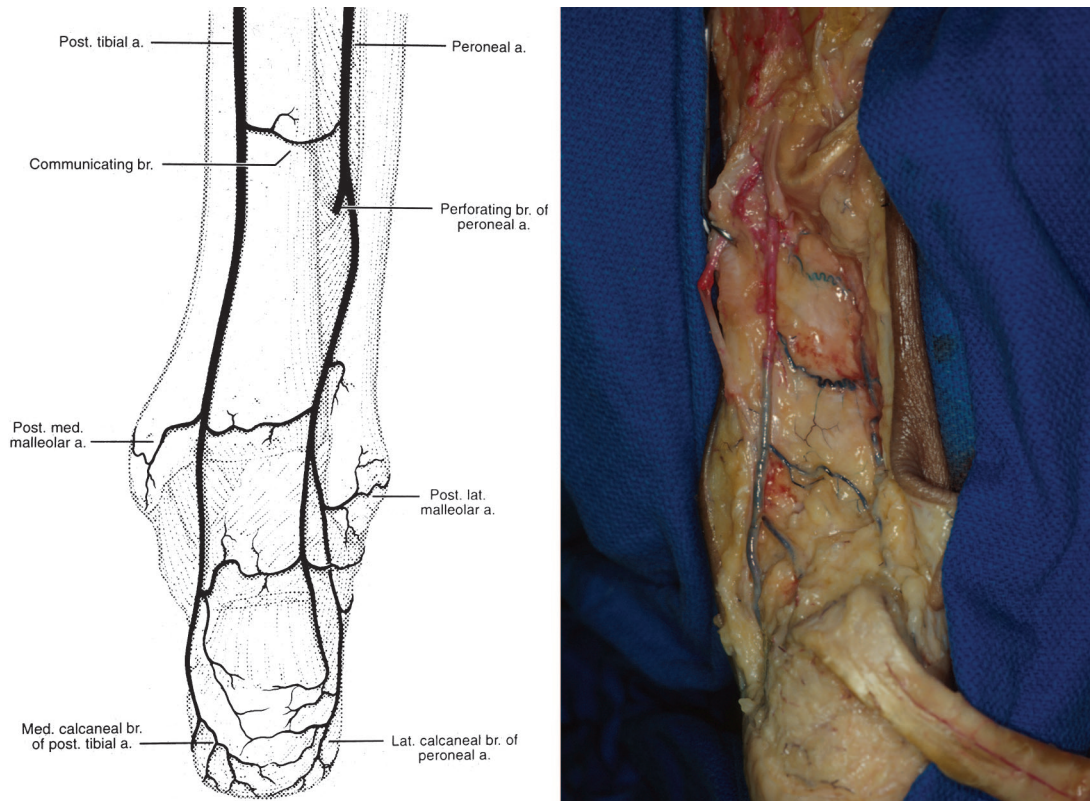


Fig. 21. The peroneal artery communicates distally with the posterior tibial artery via one to three transverse communicating branches and with the anterior tibial artery via the anterior perforating branch (Fig. 12). Reprinted with permission from Attinger, C. Vascular anatomy of the foot and ankle. *Oper. Tech. Plast. Reconstr. Surg.* 4: 183, 1997.

We have described above in detail the importance of assessing the blood flow to each angiosome. As we stated, the presence of a palpable pulse or a Doppler-detectable triphasic sound over the source artery to a given angiosome indicates adequate blood flow to that angiosome. If there is good blood flow from the source artery feeding each angiosome, the safest incisions to make are along the border between two adjacent angiosomes, because each side of the incision has maximal blood flow. Therefore, incisions along the central raphe over the Achilles tendon, along the glabrous junction separating the sole of the foot from the dorsum of the foot, or along the midline of the sole of the foot are very safe incisions.

Unfortunately, one cannot reach all areas of the foot through these incisions, and blood flow to each angiosome is not always satisfactory; thus, well-deliberated compromises need to be made. When the signal of a source artery to one of two adjacent angiosomes is absent, the affected ischemic angiosome depends on the surrounding angiosomes for blood flow via the choke vessels. Be-

cause the choke vessels require 4 to 10 days to become patent after a given angiosome becomes ischemic, incisions placed too soon after an arterial occlusion for collateral circulation to develop run the risk of poor healing, necrosis, or gangrene.^{13,14} However, in patients with chronic arteriosclerosis, the occlusion is gradual and the choke vessels are usually patent by the time the source vessel closes.

When faced with abnormal blood flow, mapping out the direction of blood flow along the main arteries of the foot and ankle is critical. Again, important information regarding arterial vessel predominance and directional flow can be obtained with the handheld Doppler device. This is not to minimize the importance of angiography in assessing vascular pathology. In the vascularly compromised patient, there may be collateral flow keeping the ischemic angiosome vascularized, and incisions must be planned so that this collateral flow is not disturbed. In the more extreme ischemic cases, in which there are no palpable pulses and the Doppler sounds are monophasic, then

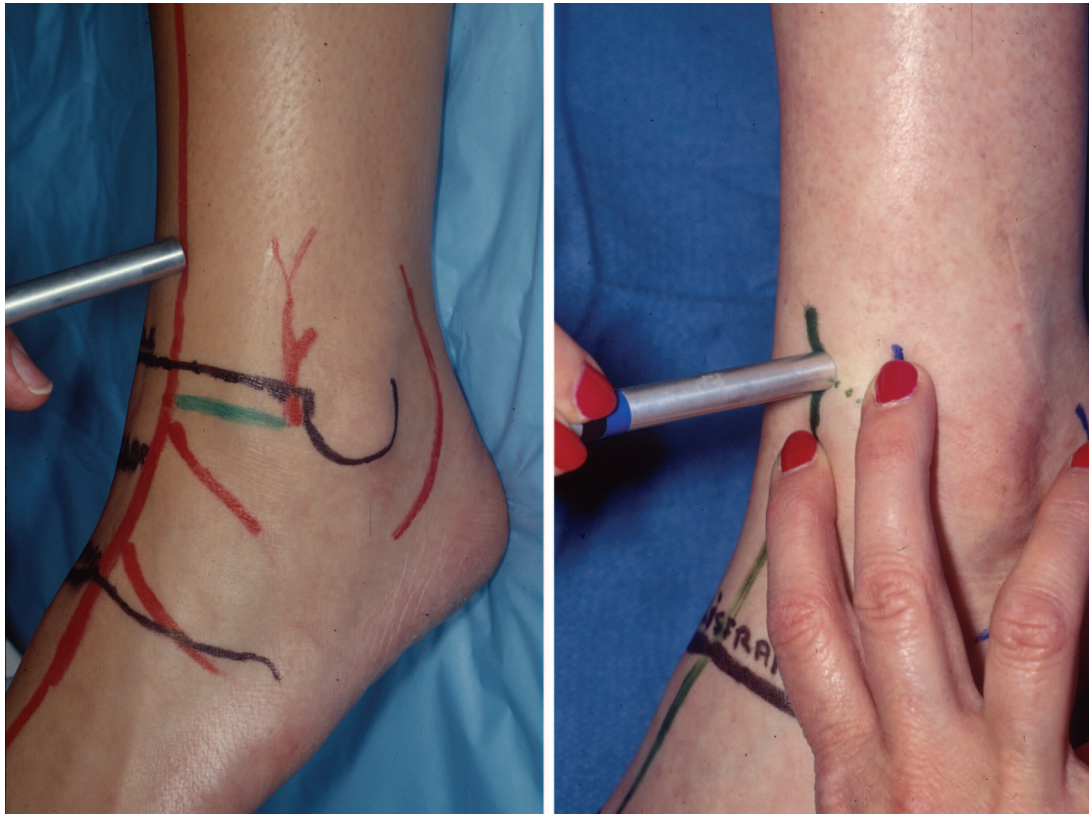


Fig. 22. The Doppler probe is placed above the ankle joint over the anterior tibial artery (*left*). The artery anterior tibial artery is occluded at the level of the lateral malleolar artery to prevent the retrograde flow from both the peroneal artery (Fig. 12) and the posterior tibial artery (Fig. 10).

possible surgical revascularization should be entertained before proceeding.

When one of the pulses is not present, it is best to place the incision away from the patent source artery, as we have previously reported.¹⁸ This is the safest location, because there is minimal risk of damaging the patent source artery or the crucial choke vessels. For example, if the peroneal artery has no signal, the incision should be placed quite lateral to the Achilles (within the peroneal artery angiosome) to allow the posterior tibial artery to feed the posterior side of the incision via the choke vessels over the central raphe of the Achilles tendon. The anterior tibial artery (via choke vessels between the peroneal and anterior tibial angiosomes) feeds the anterior side of the incision. The patency of the anterior tibial artery should be checked before making the incision. Despite all these precautions, there are still no assurances that the tissue lateral to the incision will heal uneventfully.

We will briefly discuss the most frequently used incisions and refer the reader to the article by Attinger et al.¹⁸ for a more detailed discussion.

Incisions at the Achilles Tendon

Incisions over the Achilles tendon are the safest if they are made along the midline that divides the peroneal angiosome from the posterior tibial angiosome (Fig. 32, *left*). Incisions on either side of the Achilles tendon to expose the distal tibia or fibula are also safe, provided that both the posterior tibial artery and the peroneal artery are patent. The rich interconnecting vascular plexus around the Achilles tendon keeps the skin above the Achilles tendon viable. Both a medial to lateral S-shaped incision minimizes injury to the sural nerve and lesser saphenous vein (Fig. 32, *center* and *right*). If an incision is made along the glabrous junction of the posterior heel, the medial portion of the incision should not extend to the medial edge of the Achilles tendon, to avoid damaging the medial calcaneal neurovascular structures. It is safer to make the incision laterally along the glabrous junction that represents the distal angiosome boundary of the calcaneal branch of the posterior tibial artery.

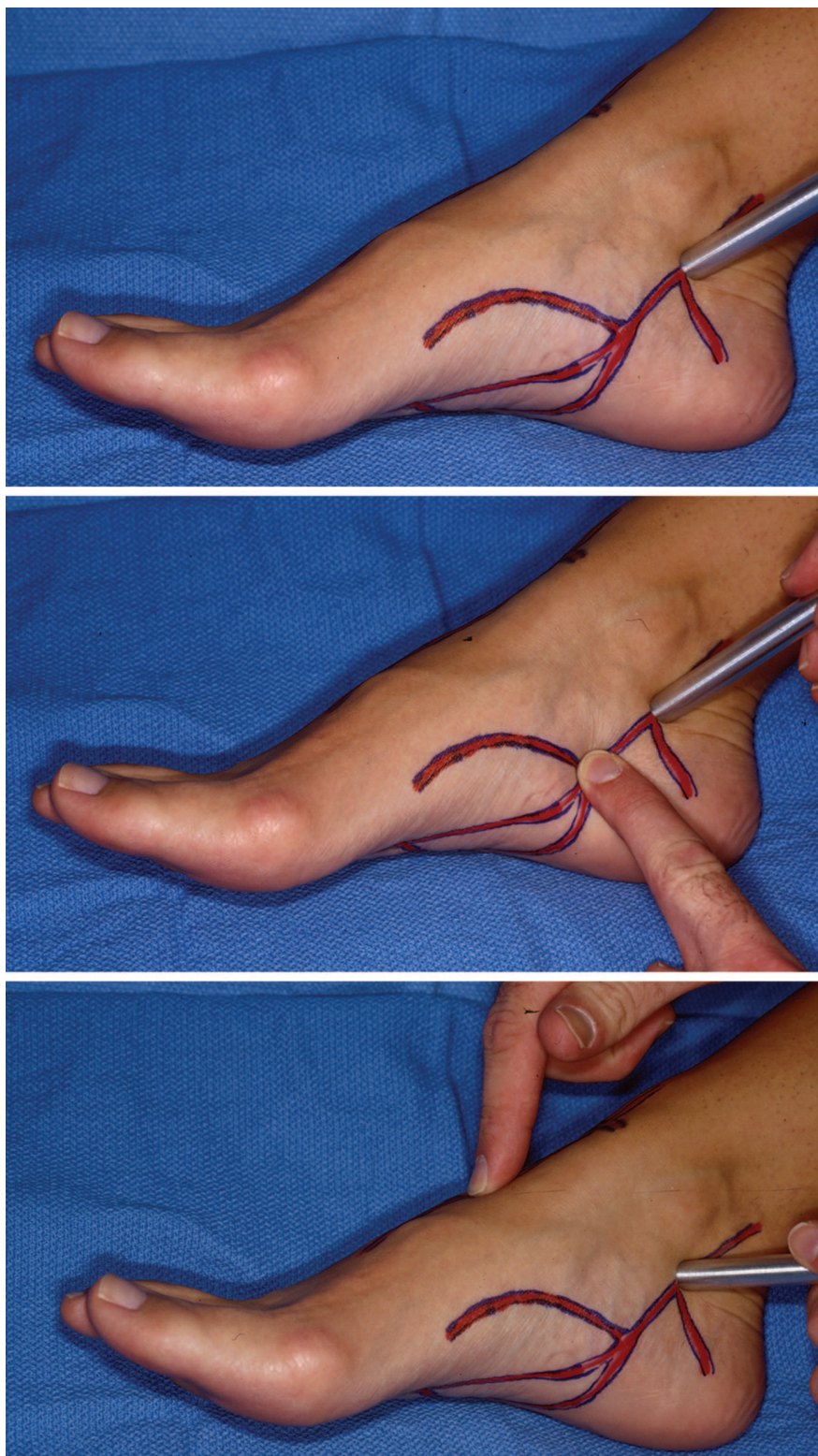


Fig. 23. The signal of the posterior tibial artery over the tarsal tunnel is located (*above*). The posterior tibial artery is then occluded distally (*center*). If there is a signal despite the distal occlusion, then there is antegrade flow along the posterior tibial artery. If there is no signal with the distal occlusion, then the flow is retrograde from the anterior tibial artery via the dorsalis pedis and lateral plantar arteries. One can alternatively listen to the posterior tibial artery and then occlude the dorsalis pedis artery (*below*). If the signal disappears, there is only retrograde flow over the posterior tibial artery from the dorsalis pedis artery.

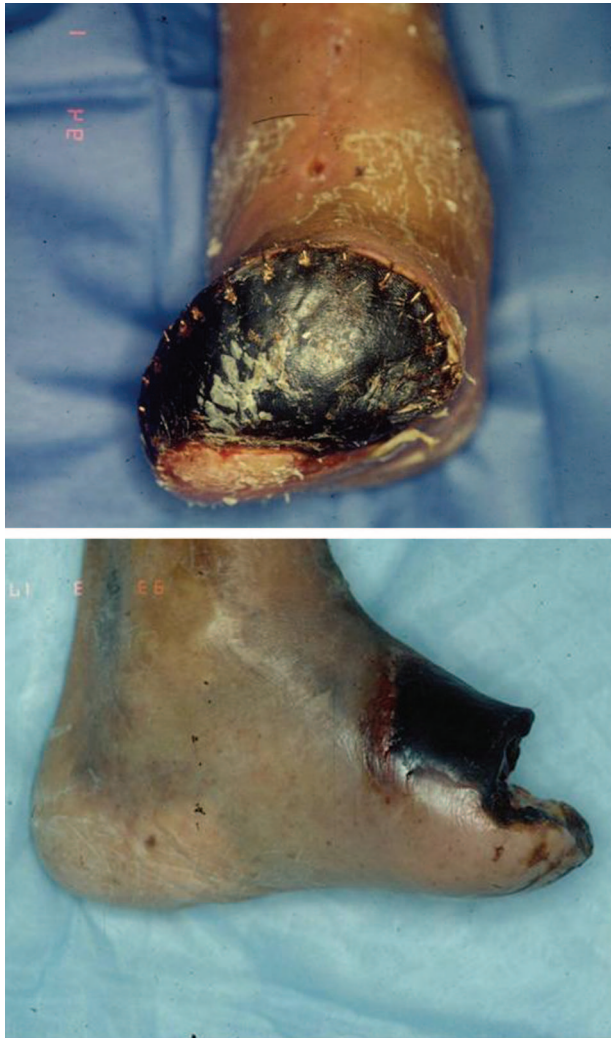

Fig. 24. (Above) This foot's plantar blood supply came from the dorsalis pedis artery via retrograde flow. When the amputation was performed and that connection was cut, the distal plantar surface went on to necrose. (Below) This foot's dorsal blood supply came from the lateral plantar artery via retrograde flow. When the amputation was performed and that connection was cut, the distal dorsal surface went on to necrose.

Incisions at the Lateral Calcaneus

To expose the lateral calcaneus in order to treat calcaneal fractures, an L-shaped incision should be used, as advocated by Benirschke and Sangeorzan.³¹ It is the safest incision if the lower portion of the incision is made along the glabrous junction between the plantar heel and the lateral heel (Fig. 33, *above*).¹⁹ Because the lateral heel glabrous juncture is the lateral border of the angiosome fed below by the calcaneal branch of the posterior tibial artery and above by the calcaneal branch of the peroneal artery, an incision above that glabrous juncture leaves the intervening tis-

sue between the glabrous junction and the incision in jeopardy (Fig. 33, *below*). In the usual trauma patient with a calcaneal fracture, the choke vessels between the posterior tibial calcaneal and peroneal calcaneal angiosomes have not had the time to open up and allow the calcaneal branch of the posterior tibial artery to feed the tissue beyond its boundary. As we stated above, it usually takes 4 to 10 days for the choke vessels to become patent, and it may take even longer in the setting of overlying soft-tissue damage and inflammation.¹³

Incisions over the Plantar Heel

In general, incisions over the plantar heel are reserved for hindfoot limb salvage in the presence of osteomyelitis. Safe incisions over the plantar heel from a vascular perspective can be coronal or sagittal in orientation, if both the posterior tibial and peroneal arteries are patent (Fig. 34, *left*). Whether the resultant scar is acceptable is another question altogether.³² Recall that the blood flow to the heel lies primarily in a coronal direction from both the calcaneal branch of the posterior tibial artery (medial) and the peroneal artery (lateral). The coronal incision will not disturb the coronal flow or the sensory nerves that travel in the same direction.

If the incision is in the sagittal direction, then the flow comes to each side of the incision from the respective calcaneal arteries. However, the sensory nerves will be damaged, which is less problematic if the patient is neuropathic. If that instance, a Gaenslen incision²⁹ down the central heel pad is the ideal choice to expose the calcaneus for calcaneotomy (Fig. 34, *right*). Taking great care to adequately evert the edges when closing the incision will avoid an inverted and chronically calloused scar.

Incisions at the Plantar Medial Midfoot

The plantar tissue is fed by perforators principally on either side of the plantar fascia (Fig. 35). If both plantar arteries open, the safest incision is along the plantar midline separating the medial plantar angiosome from the lateral plantar angiosome (Fig. 36, *left*). One can also use a curved or Z-shaped incision with the top two limbs following more or less along the boundary of the medial plantar artery (Fig. 36, *center*). If a curved incision is chosen, it should have its apex laterally based to better follow the angiosome boundary between the medial and lateral plantar arteries (Fig. 36, *right*). Care has to be taken to preserve the per-

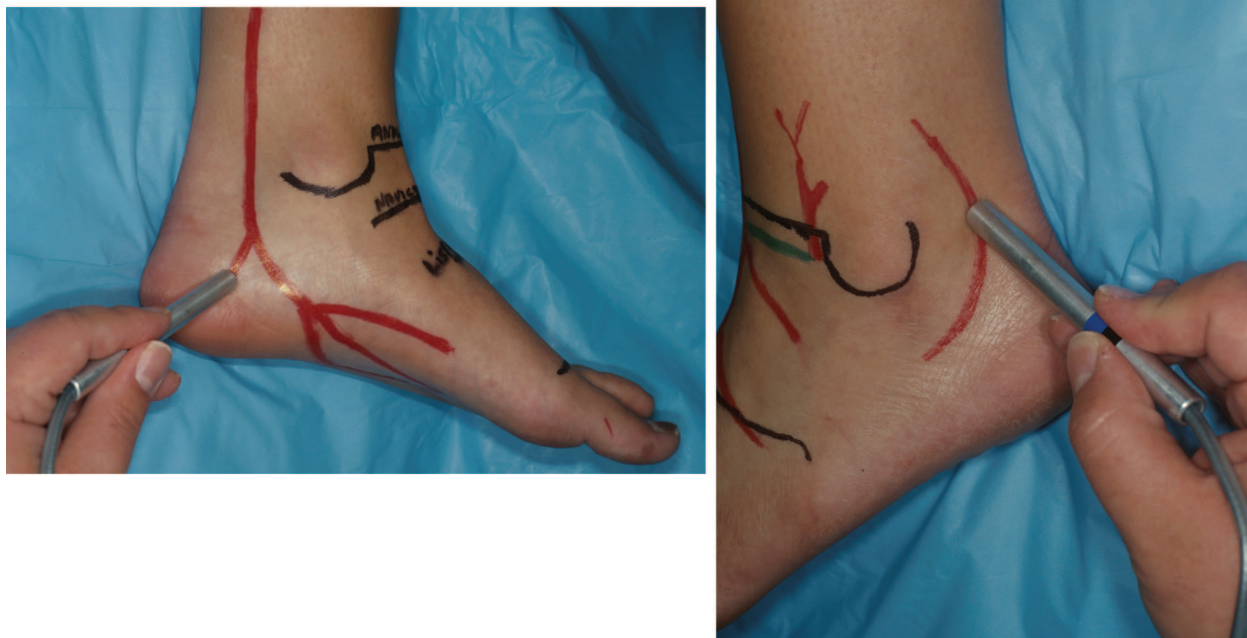


Fig. 25. (Left) The calcaneal branch of the posterior tibial artery goes directly toward the heel pad along the center of the medial heel. (Right) The calcaneal branch of the peroneal artery curves around the lateral malleolus 2 cm distal to the malleolar tip and then travels toward the proximal fifth metatarsal head.

forators along either side of the plantar fascia. Coronal incisions are also equally secure if the proximal and distal perforators or the underlying neurovascular bundles are not damaged.

Incisions along the Medial and Lateral Foot

For approaches to the medial midfoot, the incision is made along the border between the medial plantar artery angiosome and the dorsalis pedis angiosome (Fig. 5). Two to 3 cm above the medial glabrous junction is safe, provided that both the superficial and deep medial plantar arteries are open. To accurately map out the border, one should use the Doppler device to determine the course of the superficial medial plantar artery and design the incision dorsal to its course. The plantar side of the incision is then carefully lifted off the underlying bone, with care taken not to damage the superficial medial plantar artery. Alternatively, the incision can be made at the glabrous junction in the center of the medial plantar angiosome. Because two medial plantar arteries provide blood supply to the medial plantar angiosome, it is safe to make an incision in between them, provided they are both patent.

Laterally, the safest incision is along the glabrous junction at the border between the dorsal and plantar tissue (Fig. 4, *below*). The incision lies at the border between the dorsal foot angiosome (dorsalis pedis artery) and the plantar angiosome (lateral plantar artery).

Incisions on the Dorsum of the Foot

When considering dorsal foot incisions, recall that the dorsal circulation proximal to Lisfranc's joint travels in a coronal direction, and distal to Lisfranc's joint it travels in a sagittal direction (Fig. 13, *left*). The lateral proximal dorsum of the foot is composed of a rete (net) of coronally interconnected arteries of the lateral malleolar, tarsal (proximal and distal), and arcuate arteries. This rete is linked superiorly to the anterior perforating branch and laterally to the calcaneal branch of the peroneal arteries. Medial to the dorsalis pedis artery is the medial tarsal artery that may be directly linked to the superficial medial plantar artery.

Again, we advocate the principle of placing the incision parallel to the direction of the arterial supply. Coronal incisions in the lateral

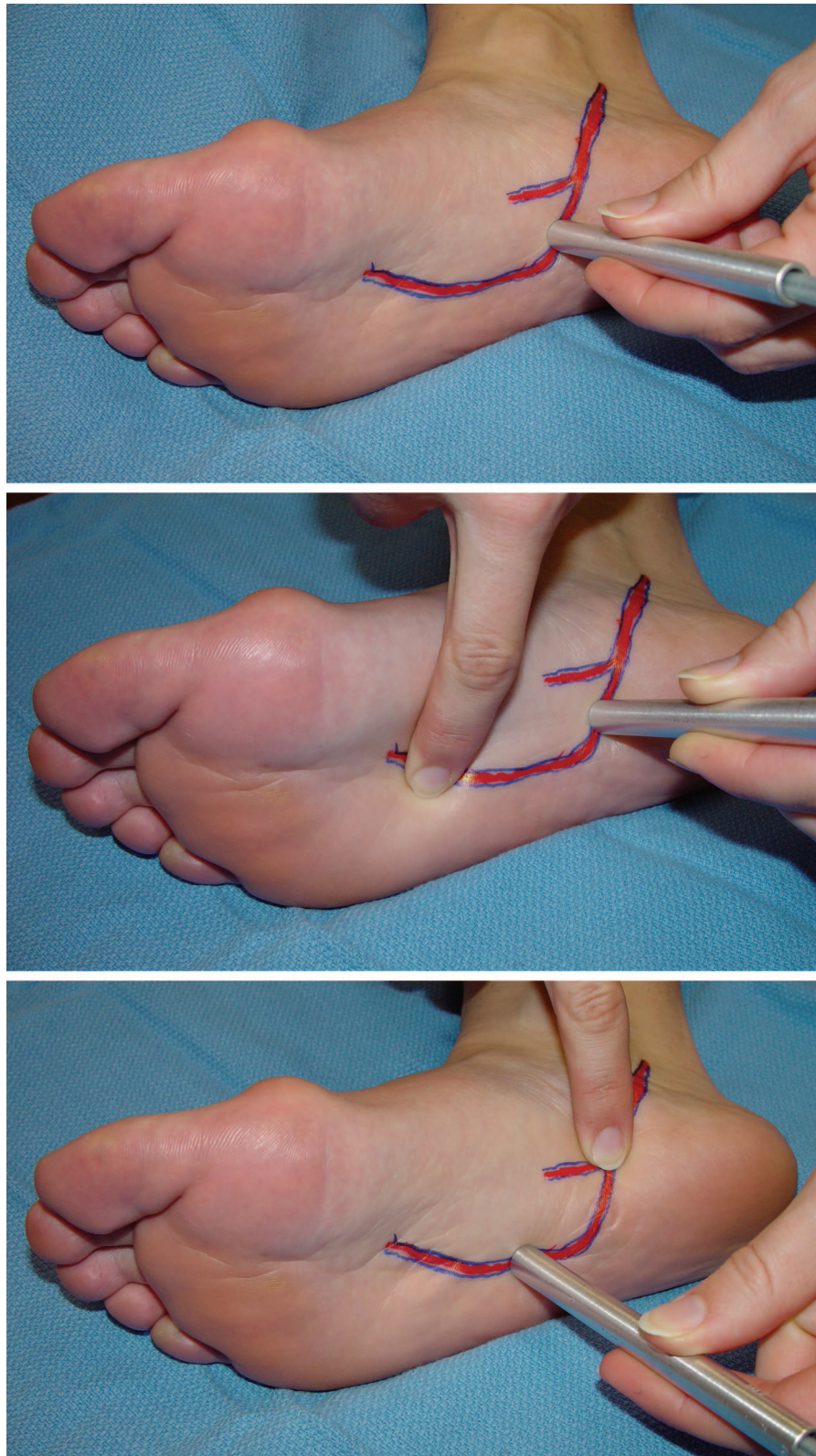


Fig. 26. (Above) The lateral plantar artery is identified by Doppler proximal to the base of the proximal first interspace. (Center) The cruate anastomosis is occluded at the level of the tarsal-metatarsal joint. If the sound remains, it means that there is antegrade flow from the distal posterior tibialis artery. (Below) To check for retrograde flow along the lateral plantar artery, the distal posterior tibial artery is occluded before the takeoff of the medial and lateral plantar arteries and the lateral plantar artery is checked by Doppler. If there is a signal, there is retrograde flow.

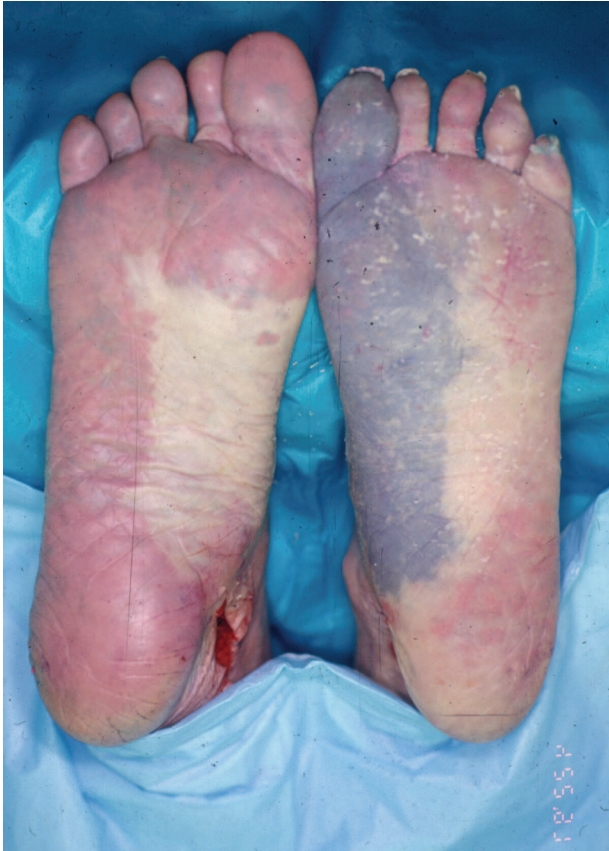

Fig. 27. Depending on what arteries predominate at or around the cruciate anastomosis, the hallux can be primarily nourished by the lateral plantar artery, medial plantar artery, or first dorsal metatarsal artery (Fig. 9, right). All of these arteries may actually supply the hallux simultaneously. This shows the duplication of blood supply to the forefoot.

proximal dorsal foot are parallel to the coronally directed arteries (proximal tarsal, distal tarsal, arcuate arteries, and their perforators). In addition, the dorsalis pedis artery should be identified and spared, unless it is clear that the antegrade and retrograde flow is strong. For approaches to the medial proximal dorsal foot, the safest incision is along the border between the medial plantar artery angiosome and the dorsalis pedis angiosome.

For incisions of the distal forefoot, it is important not to place an incision through the metatarsal arteries, unless they both have antegrade flow (from the arcuate artery and proximal perforators) and retrograde flow (from the distal perforators). Recall that the metatarsal arteries arise from the arcuate artery, travel along the interosseous space, and are connected to plantar circulation both proximally and distally by perforators. If the metatarsal artery flow is bidirectional, then

coronally directed incisions are safe but are seldom needed. However, if the flow is unidirectional, the incisions should be in the sagittal direction, over the metatarsal bones themselves, in order not to disturb the dorsal metatarsal arteries. Multiple parallel sagittal incisions over the distal dorsal forefoot can be performed as long as the dorsal metatarsal arteries are preserved. Incidentally, only three incisions are necessary to gain access to all metatarsals, and the incisions should be short, with little undermining of the skin overlying the interosseous muscles.

Incisions for Amputations

In general, performing forefoot and midfoot amputations in patients who have intact circulation with both the dorsal and plantar antegrade blood flow has minimal risk. All incisions should be designed at the angiosome boundaries to maximize blood flow at the edges of the amputation. Medial and lateral incisions should be at the glabrous juncture between the dorsal and plantar circulation, while dorsal and plantar incisions should be to bone, without undermining to preserve the metatarsal arteries in the flaps.

When there is compromised flow and a forefoot or midfoot amputation is planned, it is very important that the remaining blood flow and arterial-arterial connections are mapped completely. If the dorsal circulation depends on the plantar circulation or vice versa, then connections between the two regions cannot be disturbed (Fig. 24). That is, the connection between the dorsalis pedis and lateral plantar arteries at the proximal first interspace must be maintained. To preserve that connection when performing a short transmetatarsal or Lisfranc amputation, the lateral four metatarsals are removed laterally while the first metatarsal is removed medially.

USING THE ANGIOSOME PRINCIPLE AND CAREFUL DOPPLER EXAMINATION TO PLAN FLAP RECONSTRUCTION OF THE FOOT AND ANKLE

When planning to use a local flap in the foot and ankle, a careful Doppler examination of the foot and ankle is important. Although local flaps are random, the chance of success is improved when one can ensure that there is an open perforator at the base of the flap. If a perforator cannot be located, it is important that the underlying arterial flow toward the base of the flap be antegrade to help ensure success of the flap. If the flow is retrograde, the dissection of the distal portion of the flap may be cutting off vital

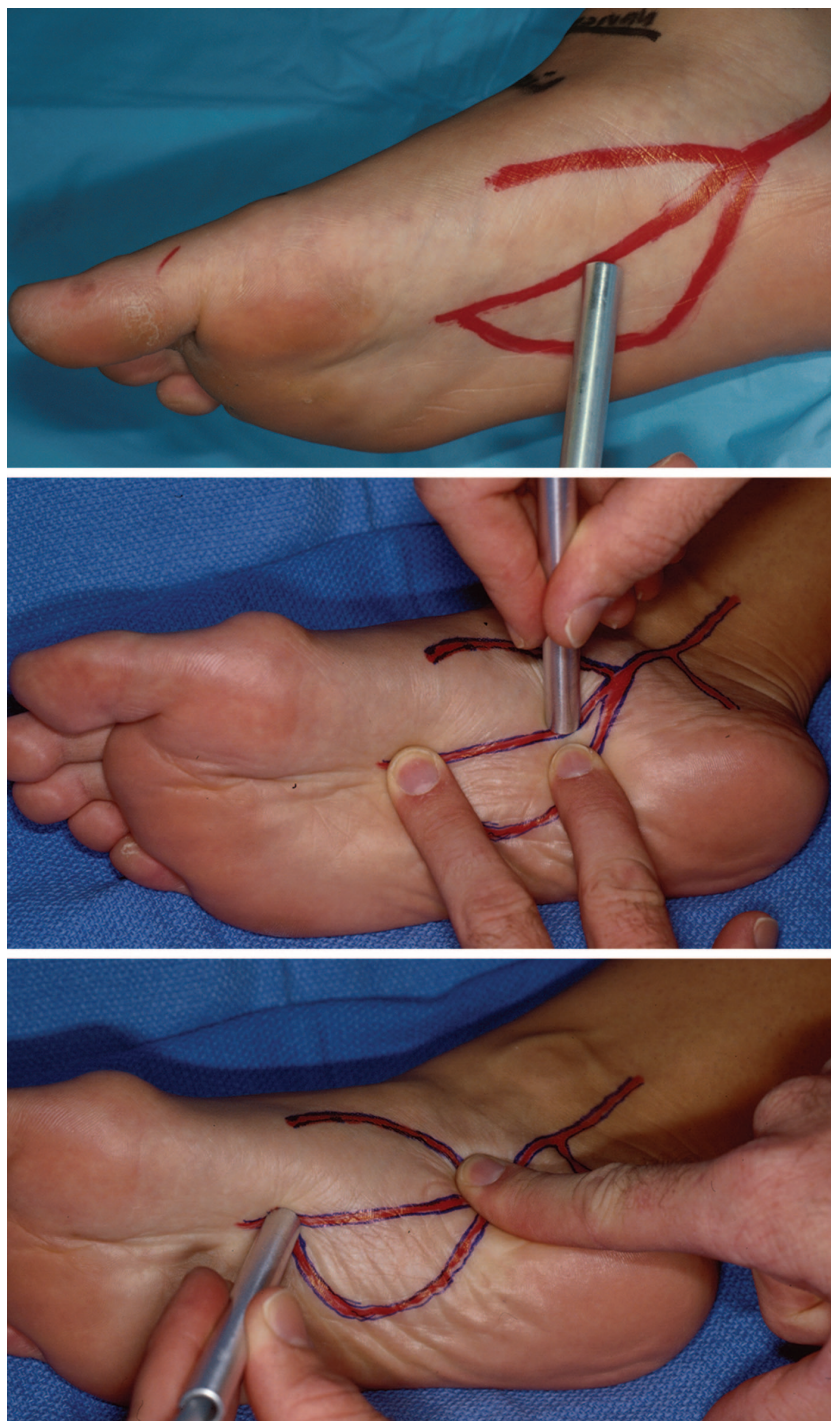


Fig. 28. (Above) The Doppler device is used on the deep medial plantar artery proximally. Pressure is applied at the cruciate anastomosis just proximal to the first metatarsal head and to the proximal lateral plantar artery simultaneously (*center*). If the signal persists, then there is antegrade flow along the deep medial plantar artery. If it disappears, then the flow is retrograde. Occluding the medial plantar arteries at their takeoff and then selectively occluding and releasing the dorsalis pedis artery and the lateral plantar artery can establish which of the two arteries can provide retrograde flow to the occluded medial plantar artery. Here the proximal medial plantar arteries and the proximal lateral plantar artery are being occluded while the Doppler device is placed on the distal deep medial plantar artery. If there is a signal, then the dorsalis pedis is the source of the retrograde flow (*below*).

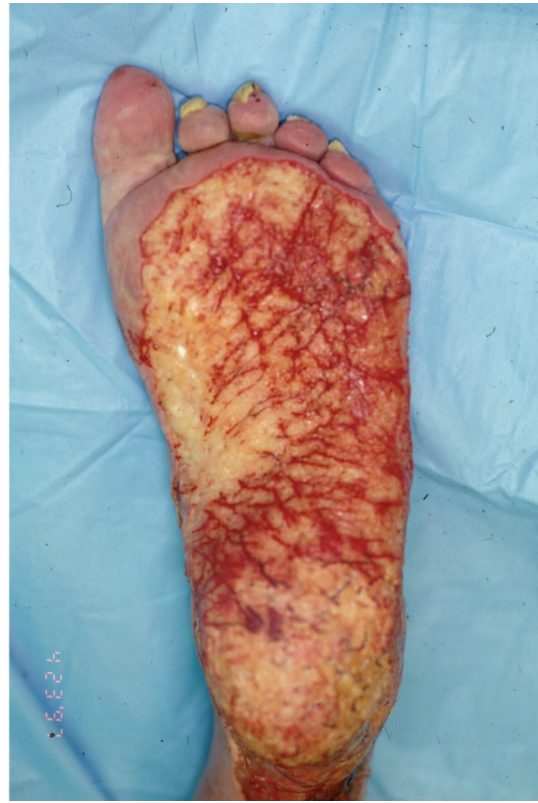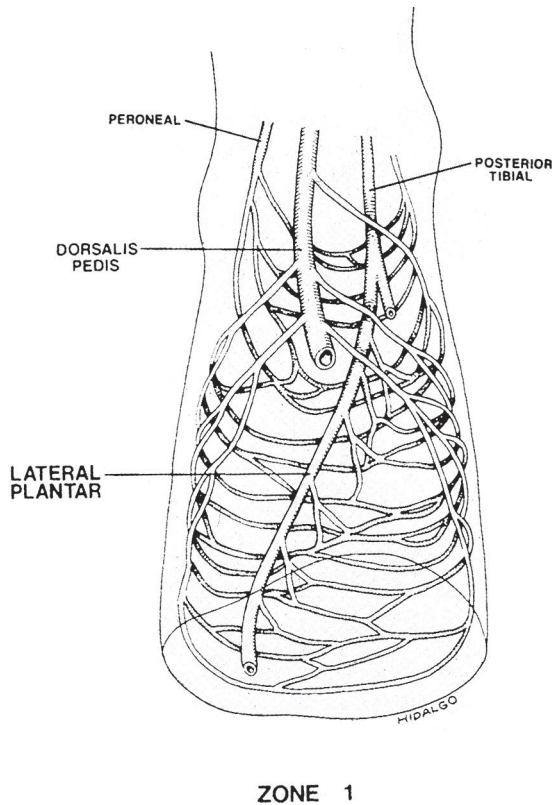


Fig. 29. Hidalgo and Shaw showed that there was a subdermal arteriolar plexus linking the dorsalis pedis with the lateral plantar artery in a circumferential wraparound pattern. This subdermal network consists of a very fine network of minute arterioles. It further protects the sole of the foot by providing another source, albeit small, of vascular inflow to the plantar skin. This flow is not of sufficient caliber to disturb the angiosome boundaries described above or to feed the entire sole of the foot, but it helps augment it via an alternative vascular pathway. Reprinted from Hidalgo, D. A., and Shaw, W. W. Anatomic basis of plantar flap design. *Plast. Reconstr. Surg.* 78: 267, 1986.

blood flow to the base of the flap necessary for its survival.

When planning a pedicled flap in a patient with an intact vascular tree, the dissection should be fairly straightforward. It is still useful to use the Doppler device to map out the vascular anatomy to ensure that the dominant pedicle of the planned flap is open. This knowledge can also help guide the surgeon as to which artery to use for a given flap: should the medial plantar flap be based on the superficial or deep medial plantar artery? Based on the Doppler examination, the exposure of the flap may change. If the medial plantar flap based on the superficial branch of the medial plantar artery is used, then the design of the flap is more anterior and medial and the proximal dissection has to be very delicate so as not to destroy the pedicle.

When dissecting out type II muscle flaps, use of the Doppler is critical in ensuring that only the minor pedicles are ligated and that the dominant pedicle is preserved. Whenever there is a question

as to whether the pedicle to be ligated is dominant or not, a vascular microclamp is placed on the pedicle and the muscle is mapped with the Doppler device. If the arterial signal does not change, the pedicle can be safely ligated. If the signal decreases significantly, further careful dissection is needed to determine whether ligation is appropriate. If the signal disappears altogether, the pedicle is most likely the dominant artery and has to be preserved.

When trying to extend the range of a given flap by sacrificing one of the major arteries to the foot (e.g., retrograde extensor hallucis muscle flap harvested with the distal portion of anterior tibial artery), it is critical to ensure that there is antegrade flow in the proximal anterior tibial artery and adequate retrograde flow from either the peroneal artery via the lateral malleolar artery or from the posterior tibial artery via the lateral plantar artery and dorsalis pedis artery. Other flaps whose range can be extended by taking the flap with the main artery and li-

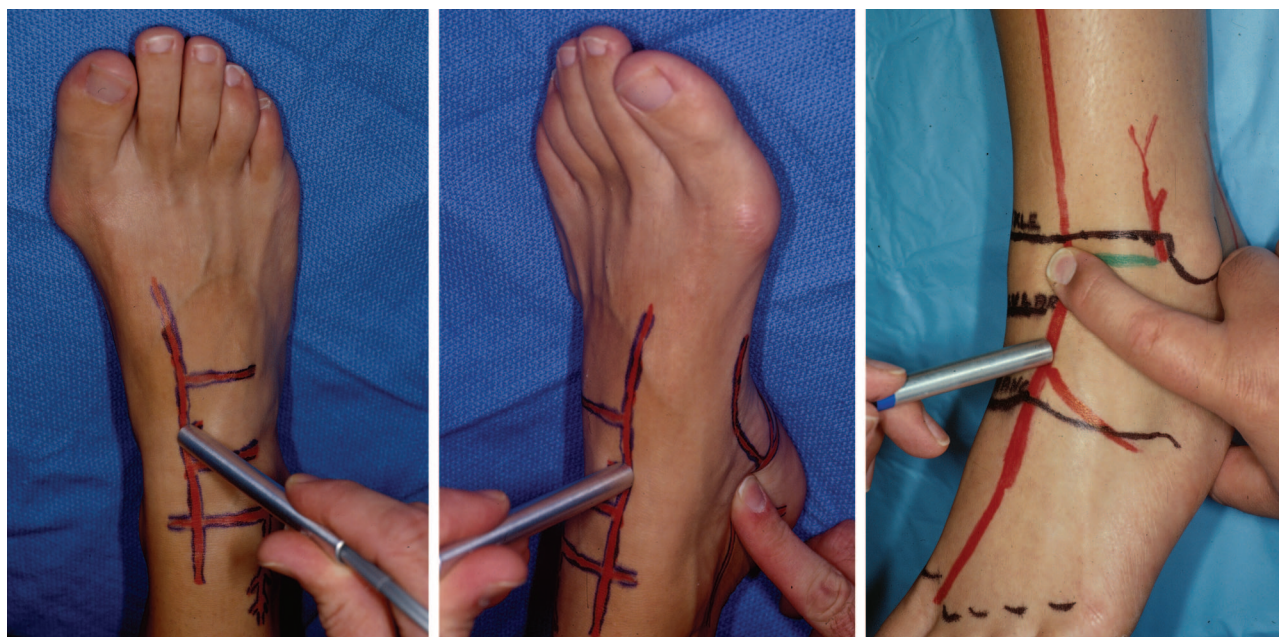

Fig. 30. (Left) The dorsalis pedis is followed using Doppler imaging proximal to Lisfranc's joint. (Center) If, when pressure is applied to the posterior tibial artery at the tarsal tunnel, the Doppler sound continues, then there is antegrade flow. If the Doppler sound disappears, then the flow to the dorsalis pedis artery is retrograde from the posterior tibial artery via the lateral plantar artery. (Right) This is confirmed by occluding the anterior tibial artery at the takeoff of the lateral malleolar artery and listening for retrograde flow from the posterior tibial artery.

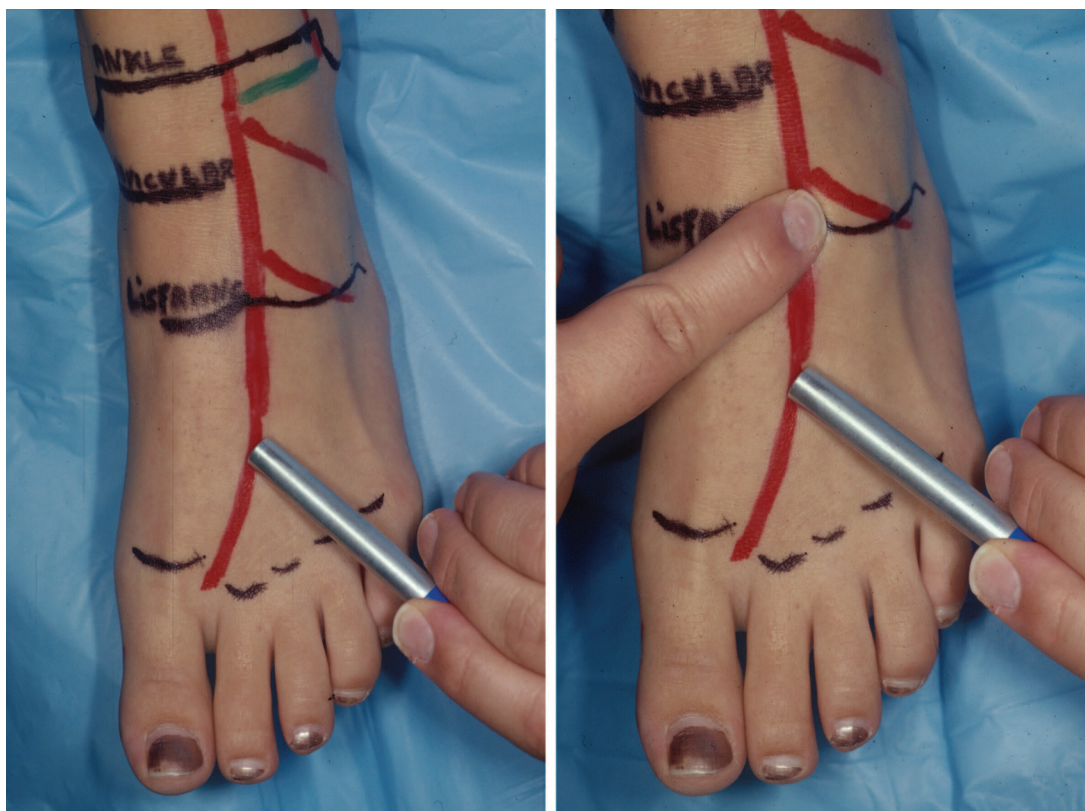


Fig. 31. The antegrade and retrograde flow of the first dorsal metatarsal artery is being evaluated. (Left) The Doppler device is placed over the artery. (Right) The dorsalis pedis is then occluded at the proximal first interspace. If there still is a signal, then there is retrograde flow from the first web space.

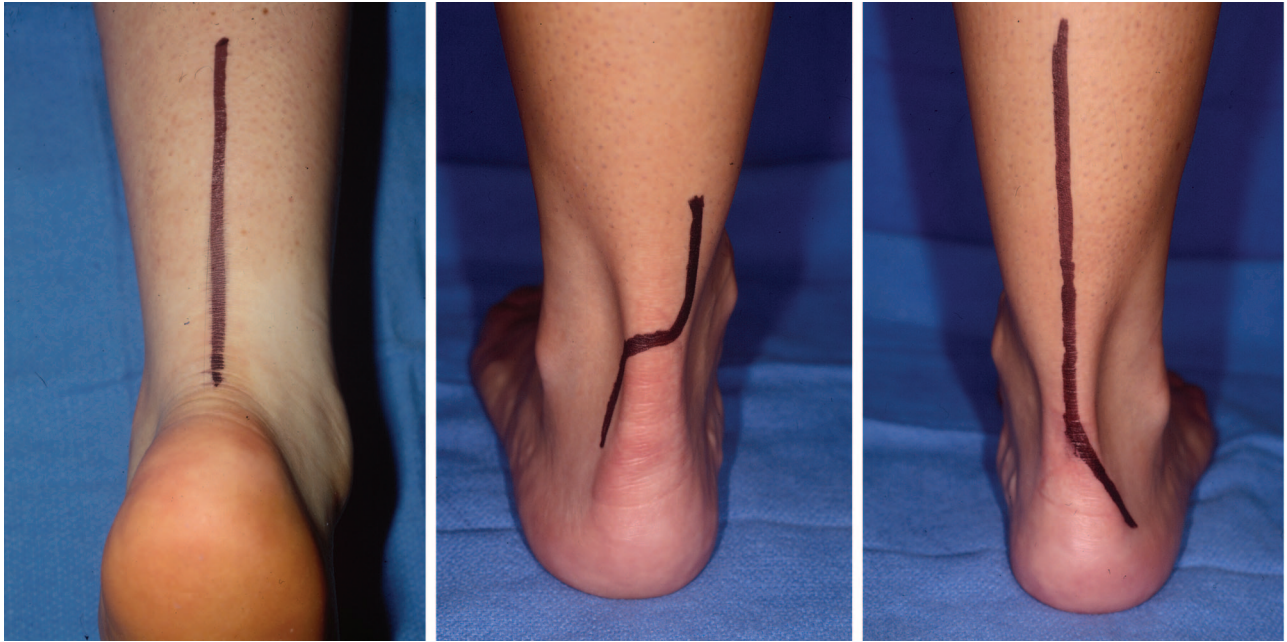


Fig. 32. Incisions over the Achilles tendon are the safest if they are made along the midline that divides the peroneal angiosome from the posterior tibial angiosome (*left*). If there is a good Doppler signal over the posterior tibial artery and the calcaneal branch of the peroneal artery, an S-shaped incision can be made starting proximally and medially and finishing laterally and distally, to avoid the sural nerve and lesser saphenous vein (*center*). Finally, if the incision has to continue distally to the level of the posterior heel, it should curve laterally along the posterior heel pad glabrous junction (*right*).

gating the other main branches include the medial plantar flap, the abductor hallucis muscle flap, the extensor digitorum brevis muscle flap, and the supramalleolar flap. Because the sacrifice of a major artery to the foot can lead to complications when the patient later develops peripheral artery disease, serious consideration should be given to using a free flap with an end-to-side arterial anastomosis instead.

Doppler examination becomes all the more critical when dealing with the vascularly compromised foot. One has to make sure that there is inflow to the planned flap and that the dissection of the flap will not interrupt critical flow to the rest of foot. For example, if the dorsum of the foot depends on the posterior tibial artery via the medial plantar artery flow, the medial plantar flap is not an option. If the anterior tibial artery is providing flow to the plantar foot via the dorsalis pedis artery, the dorsalis pedis flap cannot be used. When planning an incision to harvest a muscle flap, one has to be sure that there is inflow on either side of the incision. Using the angiosome boundaries for exposure is usually safe and should minimize vascular compromise, because the dissection usually does not sacrifice key arterial-arterial connections. Examples of incisions that are usually safe

include an those along the glabrous junction medially for the abductor hallucis muscle, along the glabrous junction laterally for the abductor digiti minimi muscle, and along the center of the plantar midfoot for the flexor digitorum muscle flap.

When coordinating a reconstruction with a foot and ankle surgeon, make sure that the skeletal exposure does not compromise a flap that you may be planning to use to close the resulting defect. If an Ilizarov frame is used, make sure the fine wires are not going through the flap that you are planning to use later. Often spared is the abductor hallucis or abductor digiti minimi flap. When planning a local flap around the ankle, coordination of pin placement is critical, so that the flap can be adequately mobilized.

USING THE ANGIOSOME PRINCIPLE IN PLANNING THE OPTIMAL REVASCULARIZATION

Despite the current advances in revascularization techniques, vascular bypass surgery fails to heal approximately 15 percent of ischemic lower extremity wounds with a patent bypass.²⁸⁻⁴³ Gooden et al. found that up to 25 percent of patients with heel ulcers ultimately succumbed to a proximal leg amputation despite a palpable pedal pulse.⁴⁴ The fail-

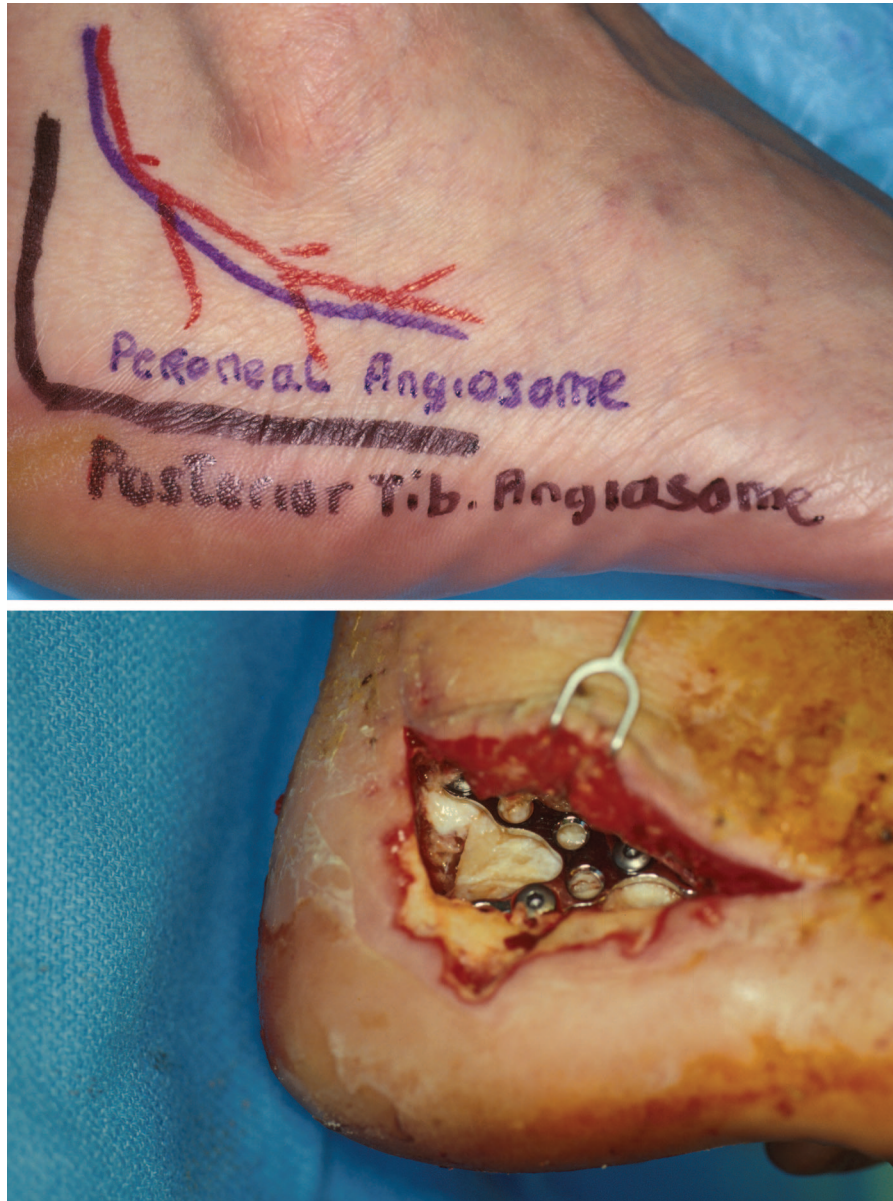

Fig. 33. The L-shaped incision, advocated by Benirschke and Sangeorzan, to expose the lateral calcaneus in calcaneus fractures should be designed with the lower portion of the incision along the glabrous junction between the plantar heel and the lateral heel (*above*). The lateral heel glabrous junction is the boundary that represents the lateral extent of the angiosome fed by the calcaneal branch of the posterior tibial artery. An incision above the glabrous junction into the lateral heel proper leaves the tissue between the glabrous junction and the incision in jeopardy, because that tissue lies in the just-divided angiosome of the calcaneal branch of the peroneal artery (*below*).

ures may be due in part to inadequate postoperative wound care,⁴⁵ but part of the problem may also be due to the inadequate revascularization of the local ischemic area, because the vascular connections between the revascularized vessel and the source vessel nourishing the ischemic area are occluded. Thus, successful revascularization for ischemic wounds ob-

viously is more complex than simply restoring circulation to a specific artery.

The failure of limb salvage in a percentage of successful bypasses suggests that more effective revascularization may occur if the bypassed vessel directly feeds the source artery of the angiosome containing the ulceration. That is, revasculariza-

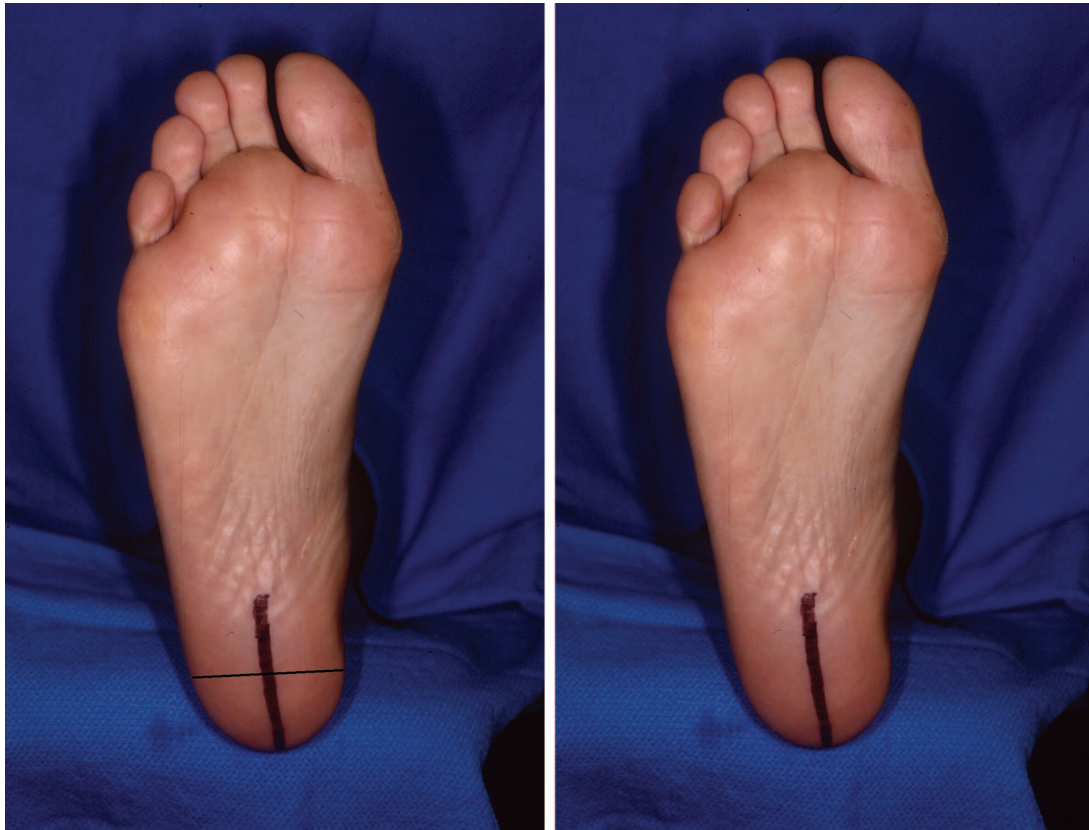


Fig. 34. A vascularly safe incision over the plantar heel can be in either a coronal or sagittal direction if both calcaneal arteries are patent (*left*). Coronally placed incisions minimize the damage to the sensory nerves. The midline sagittal incision (Gaenslen) offers excellent calcaneal exposure for calcanectomy (*right*).

tion of the major artery *directly* supplying the ischemic and ulcerated angiosome should be more successful than revascularizing one of the other two major arteries and depending on arterial-arterial connections for the blood flow to reach the ischemic ulcerated angiosome.⁴⁶ We retrospectively examined the results of direct versus indirect consecutive revascularization of 52 limbs. There was a 9.1 percent failure rate when wounds were directly revascularized versus a 38.1 percent failure rate in the wounds indirectly bypassed ($p = 0.03$). Those who failed to heal went on to a major leg amputation. The amputation rate, therefore, in the indirectly bypassed group was four times that of the directly bypassed group. This study supports the suggestion that direct revascularization of the affected angiosome leads to higher limb salvage rates.

If the vascular surgeon has more than one vessel to bypass to, or has the choice of endovascularly opening more than one vessel, he or she should preferentially open the vessel that directly feeds the affected angiosome. For heel wounds, the peroneal or posterior tibial artery should be

preferentially revascularized. For plantar foot wounds, the posterior tibial artery should be preferentially revascularized. For lateral ankle wounds, the peroneal artery should be preferentially revascularized. For dorsal foot wounds, the anterior tibial artery should be preferentially revascularized.

If the vascular surgeon cannot revascularize the source artery to the affected angiosome, he or she can then predict a certain failure rate from an alternative bypass (≥ 15 percent), unless the surgeon can demonstrate that the arterial-arterial connections between the artery to be revascularized and the source artery of the affected angiosome are open.

CONCLUSIONS

In the normal patient, blood flow to the foot and ankle is redundant, with three major arteries feeding the foot via multiple arterial-arterial connections. By having a thorough grasp of those arterial-arterial interconnections and by selectively using the Doppler device to identify those connections, it is possible to map out the existent

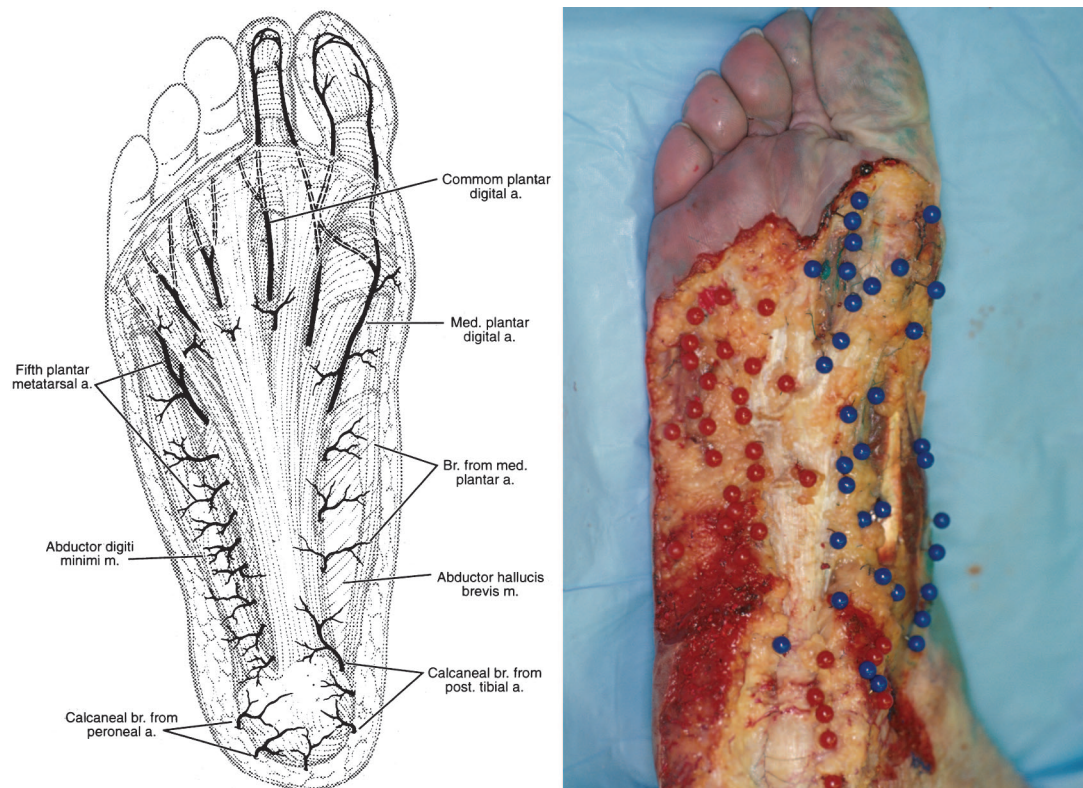


Fig. 35. Most of the perforators that feed the plantar midfoot arise along each side of the plantar fascia from the lateral plantar artery and deep medial plantar artery (*left*). The different colored pins show the location of the perforators on either side of the plantar fascia (*right*). Reprinted with permission from Attinger, C. Vascular anatomy of the foot and ankle. *Oper. Tech. Plast. Reconstr. Surg.* 4: 183, 1997.

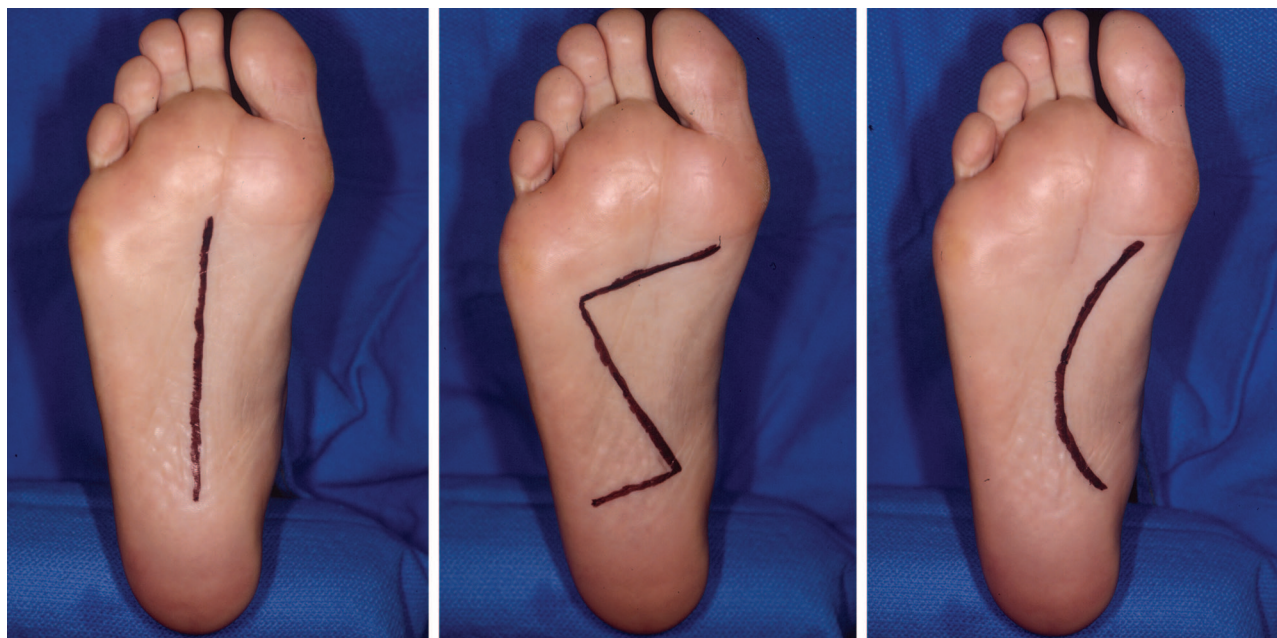


Fig. 36. (*Left*) A straight incision down the midline of the sole of the foot is the safest from a vascular perspective. (*Center*) One can also use a curved or Z-shaped incision with the top two limbs following more or less along the boundary of the medial plantar artery. (*Right*) If a curved incision is chosen, it should have its apex laterally based, so as to better follow the angiosome boundary between the medial and lateral plantar arteries.

vascular tree, including the direction of flow. By adding the concept of the angiosome to the Doppler examination, one can optimize the success of any planned treatment or procedure. The incision can be placed in a location to ensure that the blood flow on either side of the incision is optimal. Flaps can be dissected out with a high degree of reliability. Amputations can be performed in a way that minimizes the risk of distal tissue necrosis. The revascularization can be planned to increase the healing of a given wound or ulcer.

This detailed knowledge of vascular anatomy helps the clinician make better decisions when dealing with limb salvage. The surgeon can better estimate the success of various procedures and decide which type of reconstruction has the most chance of success, given the existing blood supply. He or she can better determine when salvage is not possible and recommend amputation rather than lengthy, costly, and potentially dangerous procedures with little chance of success.

Christopher E. Attinger, M.D.

The Limb Center
Georgetown University Medical Center
3800 Reservoir Road, NW
Washington, D.C. 20007
cattinger@aol.com

REFERENCES

- Morain, W. D., and Ristic, J. *Manchot: The Cutaneous Arteries of the Human Body*. New York: Springer Verlag, 1983.
- Salmon, M. *Arteries of the Skin* (Taylor, G. I., and Tempest, M. N., Eds.). Edinburgh: Churchill Livingstone, 1988.
- McGregor, I. A., and Morgan, G. Axial and random pattern flaps. *Br. J. Plast. Surg.* 26: 202, 1973.
- Daniel, R. K., Cunningham, D. M., and Taylor, G. I. The deltopectoral flap: An anatomical and hemodynamic approach. *Plast. Reconstr. Surg.* 55: 275, 1975.
- Mathes, S. J., and Nahai, F. *Clinical Atlas of Muscle and Musculocutaneous Flaps*. St. Louis, Mo.: Mosby, 1979.
- Ger, R. Operative treatment of the advanced stasis ulcer using muscle transposition. *Am. J. Surg.* 120: 376, 1970.
- Orticochea, M. The musculocutaneous flap method: An immediate and heroic substitute for the method of delay. *Br. J. Plast. Surg.* 25: 106, 1972.
- McCraw, J. B., and Dibell, D. G. Experimental definition of independent myocutaneous vascular territories. *Plast. Reconstr. Surg.* 60: 341, 1977.
- Taylor, G. I., and Palmer, J. H. The vascular territories (angiosomes) of the body: Experimental studies and clinical applications. *Br. J. Plast. Surg.* 43: 1, 1990.
- Taylor, G. I., and Minabe, T. The angiosomes of the mammals and other vertebrates. *Plast. Reconstr. Surg.* 89: 181, 1992.
- Calligari, P. R., Taylor, G. I., Caddy, C. M., and Minabe, T. An anatomic review of the delay phenomenon: I. Experimental studies. *Plast. Reconstr. Surg.* 89: 397, 1992.
- Taylor, G. I., Corlett, R. J., Caddy, C. M., and Zelt, R. G. An anatomic review of the delay phenomenon: II. Clinical applications. *Plast. Reconstr. Surg.* 89: 408, 1992.
- Morris, S. F., and Taylor, G. I. The time sequence of the delay phenomenon: When is a surgical delay effective? An experimental study. *Plast. Reconstr. Surg.* 95: 526, 1995.
- Dhar, S. C., and Taylor, G. I. The delay phenomenon: The story unfolds. *Plast. Reconstr. Surg.* 104: 2079, 1999.
- Sarrafian, S. K. *Anatomy of the Foot and Ankle*. Philadelphia: Lippincott, 1993. Pp. 294–355.
- Taylor, G. I., and Pan, W. R. Angiosomes of the leg: Anatomic study and clinical implications. *Plast. Reconstr. Surg.* 102: 599, 1998.
- Attinger, C. E., Cooper, P., and Blume, P. Vascular anatomy of the foot and ankle. *Oper. Tech. Plast. Reconstr. Surg.* 4: 183, 1997.
- Attinger, C. E., Cooper, P., Blume, P., and Bulan, E. The safest surgical incision and amputations applying the angiosomes principle and using the Doppler to assess the arterial-arterial connections of the foot and ankle. *Foot Ankle Clin. North Am.* 6: 745, 2001.
- Attinger, C., and Cooper, P. Soft tissue reconstruction for calcaneal fractures or osteomyelitis. *Orthop. Clin. North Am.* 32: 135, 2001.
- Murakami, T. On the position and course of the deep plantar arteries, with special reference to the so called plantar metatarsal arteries. *Okajimas Folia Anat. Jpn.* 48: 295, 1971.
- Huber, J. F. The arterial network supplying the dorsum of the foot. *Anat. Rec.* 80: 373, 1941.
- Adachi, B. *Das Arteriensystem der Japaner*. Kyoto: Maruzen, 1928. Pp. 246–248.
- May, J. W., Chait, L. A., and Cohen, B. E. Free neurovascular flap from the first web of the foot in hand reconstruction. *J. Hand Surg. (Am.)* 5: 387, 1977.
- Shusterman, M. A., Reece, G. P., and Miller, M. J. The osteocutaneous free fibula flap: Is the skin paddle reliable? *Plast. Reconstr. Surg.* 90: 787, 1992.
- Jones, N. F., Monstrey, M. D., and Gambier, B. A. Reliability of the fibular osteocutaneous flap for mandibular reconstruction: Anatomical and surgical confirmation. *Plast. Reconstr. Surg.* 97: 707, 1996.
- Masqualet, A. C., Beveridge, J., and Romana, C. The lateral supramalleolar flap. *Plast. Reconstr. Surg.* 81: 74, 1988.
- Taylor, G. I., Doyle, M., and McCarten, G. The Doppler probe for planning flaps: Anatomical study and clinical applications. *Br. J. Plast. Surg.* 43: 1, 1990.
- Berceli, S. A., Chan, A. K., Pomposelli, F. B., et al. Efficacy of dorsal pedal artery bypass in limb salvage for ischemic heel ulcers. *J. Vasc. Surg.* 30: 499, 1999.
- Gaenslen, F. J. Split heel approach in osteomyelitis of the os calcis. *J. Bone Joint Surg.* 13: 759, 1931.
- Hidalgo, D. A., and Shaw, W. W. Anatomic basis of plantar flap design. *Plast. Reconstr. Surg.* 78: 267, 1986.
- Benirschke, S. K., and Sangeorzan, B. J. Extensive intra-articular fractures of the foot: Surgical management of calcaneal fractures. *Clin. Orthop.* 291: 128, 1993.
- Jahss, M. H. Surgical principles and the plantigrade foot. In M. H. Jahss (Ed.), *Disorder of the Foot and Ankle: Medical and Surgical Management*, 2nd Ed. Philadelphia: Saunders, 1991. Pp. 236–279.
- Treiman, G. S., Oderich, G. S., Ashrafi, A., and Schneider, P. A. Management of ischemic heel ulceration and gangrene: An evaluation of factors associated with successful healing. *J. Vasc. Surg.* 31: 1110, 2000.

34. Carsten, C. G., III, Taylor, S. M., Langan, E. M., III, and Crane, M. M. Factors associated with limb loss despite a patent infrainguinal bypass graft. *Am. Surg.* 64: 33, 1998.
35. Edwards, J. M., Taylor, L. M., and Porter, J. M. Limb salvage in end-stage renal disease (ESRD), comparison of modern results in patients with and without ESRD. *Arch. Surg.* 123: 1164, 1998.
36. Chang, B. B., Paty, P. K., Shah, D. M., Kaufman, J. L., and Leather, R. P. Results of infrainguinal bypass for limb salvage in patients with end-stage renal disease. *Surgery* 108: 742, 1990.
37. Andros, G., Harris, R. W., Dulawa, L. B., et al. The need for arteriography in diabetic patients with gangrene and palpable foot pulses. *Arch. Surg.* 119: 1260, 1984.
38. Johnson, B. L., Glickman, M. H., Bandyk, D. F., and Esses, G. E. Failure of foot salvage in patients with end-stage renal disease after surgical revascularization. *J. Vasc. Surg.* 22: 280, 1995.
39. Elliot, B. M., Robison, J. G., Brothers, T. E., and Cross, M. A. Limitations of peroneal artery bypass grafting for limb salvage. *J. Vasc. Surg.* 18: 881, 1993.
40. Bergamini, T. M., George, S. M., Massey, H., et al. Pedal or peroneal bypass: Which is better when both are patent? *J. Vasc. Surg.* 20: 347, 1994.
41. Seeger, J. M., Pretus, H. A., Carlton, L., et al. Potential predictors of outcome in patients with tissue loss who undergo infrainguinal vein bypass grafting. *J. Vasc. Surg.* 30: 427, 1999.
42. Darling, R. C., III, Chang, B. B., Paty, P. S., et al. Choice of peroneal or dorsalis pedis artery bypass for limb salvage. *Am. J. Surg.* 170: 109, 1995.
43. Abou-Zamzam, A. M., Moneta, G. L., Lee, R., et al. Peroneal bypass is equivalent to inframalleolar bypass for ischemic pedal gangrene. *Arch. Surg.* 131: 894, 1996.
44. Gooden, M. A., Gentile, A. T., Mills, J. L., et al. Free tissue transfer to extend the limits of limb salvage for lower extremity tissue loss. *Am. J. Surg.* 174: 644, 1997.
45. Attinger, C. E., Ducic, I., Neville, R. F., Abbruzzese, M. R., Gomes, M., and Sidawy, A. N. The relative roles of aggressive wound care versus revascularization in salvage of the threatened lower extremity in the renal failure diabetic patient. *Plast. Reconstr. Surg.* 109: 1281, 2002.
46. Bulan, E. J., Attinger, C. E., Ducic, I., Neville, R., Thomassen, M., and Sidawy, A. N. Implications of direct versus indirect revascularization of the ulcerated ischemic angiosome in limb salvage. Submitted for publication.