The Lower-Extremity Allen Test

Nicholas T. Haddock, M.D.,[1] Evan S. Garfein, M.D.,[2] Pierre B. Saadeh, M.D.,[1] and Jamie P. Levine, M.D.[1]

ABSTRACT

The Allen test is used to diagnose the relative contribution of the ulnar and radial arteries to each hand. We modified this test to investigate the relative vascular contributions to distal perfusion of the lower extremity. With the patient supine, a handheld Doppler is used to locate the first dorsal metatarsal artery. The posterior tibial artery (PT) and dorsalis pedis artery (DP) pulses are compressed. A persistent signal indicates collateral flow through the peroneal artery (PA). Sequential decompression is then used to evaluate the relative contribution of the PT and DP to distal circulation. We report a case in which angiography failed to predict reliance on the PT. In this case, performance of the lower-extremity Allen test (LEAT) led to an alternative recipient vessel choice. The LEAT is simple to perform and provides a valuable adjunct to angiographic data.

KEYWORDS: Lower-extremity reconstruction, Allen test, vascular exam, arterial supply

The Allen test was first described in 1929 by Edgar Allen, a physician at the Mayo Clinic.[1,2] The test originally involved simultaneous testing of both hands to assess the radial artery contribution to distal circulation. The test was later modified to diagnose the relative contribution of the ulnar and radial arteries of each hand to its distal perfusion.[3,4]

The Allen test is based on interconnectivity between the radial and ulnar arteries through the palmar arches. This same abundant vascular interconnectivity exists in the lower extremity between major arteries to the lower extremity: the anterior tibial artery (AT), posterior tibial artery (PT), and peroneal artery (PA).[5] We modified the Allen test concept to investigate the relative contribution of the PT and AT to distal perfusion of the lower extremity.

There are several ways to evaluate the vascular status of the lower extremity, ranging from physical exam with pedal pulse evaluation to invasive tests, such as angiography. Other common tests include ankle/brachial indices, directional Doppler flow studies, toe pressures and magnetic resonance angiography, and computed tomographic angiography.[6–11] Each of these tests helps define the anatomy and aids in the evaluation of healing potential, but these tests may fall short in addressing specific functional changes in lower-extremity circulation. This is particularly relevant in the selection of an appropriate recipient vessel during planning for free tissue transfer.

[1]New York University Langone Medical Center, Institute of Reconstructive Plastic Surgery, New York, New York; [2]Montefiore Medical Center, Bronx, New York.

Address for correspondence and reprint requests: Jamie P. Levine, M.D., Institute of Reconstructive Plastic Surgery, New York University Medical Center, 560 First Avenue—TCH-169, New York, NY 10016 (e-mail: Jamie.Levine@nyumc.org).

J Reconstr Microsurg 2009;25:399–404.

Received: November 3, 2008. Accepted after revision: February 3, 2009. Published online: April 23, 2009.
DOI 10.1055/s-0029-1220861. ISSN 0743-684X.

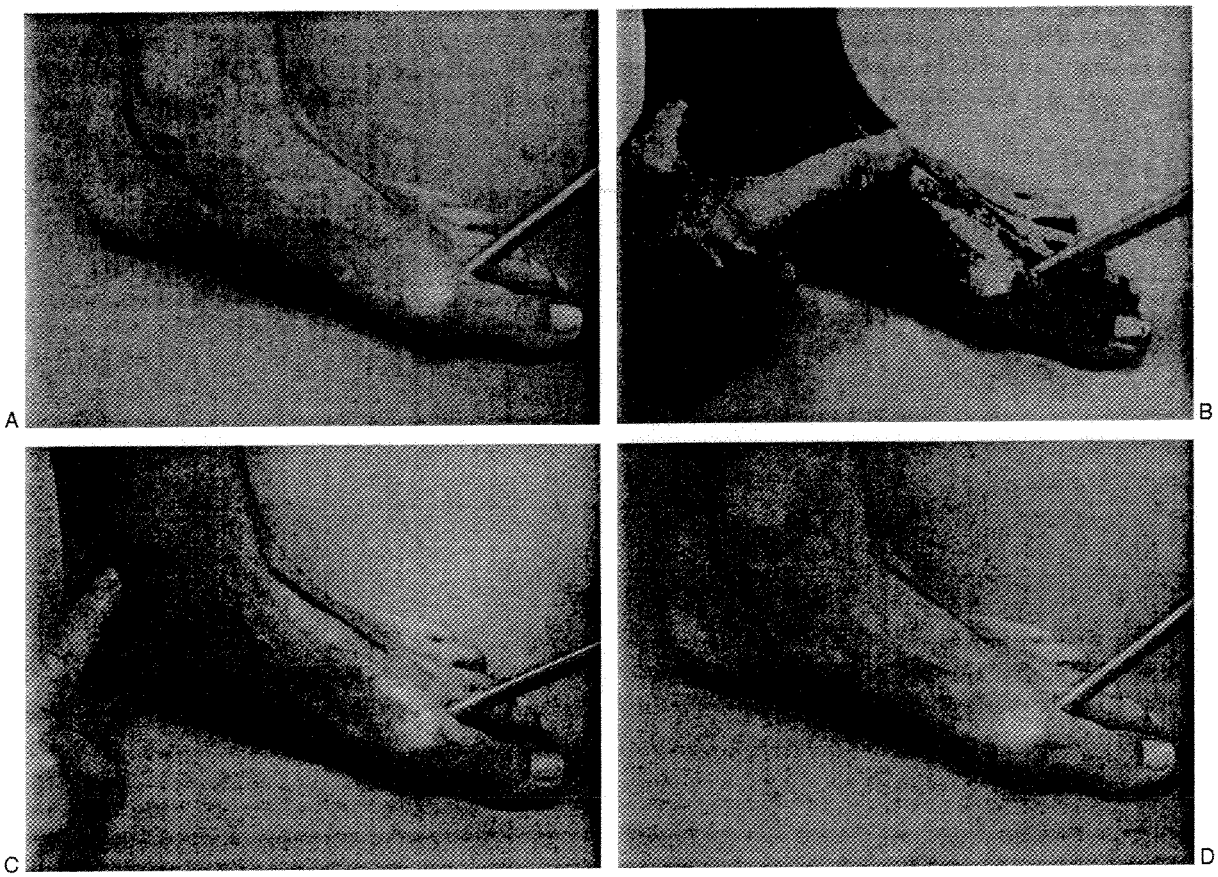

Figure 1 (A) A handheld Doppler is used to locate the first dorsal metatarsal artery. (B) The posterior tibial artery (PT) and the dorsalis pedis artery (DP) pulses are simultaneously palpated and compressed. A persistent signal indicates collateral flow through the peroneal artery. (C) If the signal is extinguished, pressure on the DP artery is released. Return of a signal indicates adequate DP flow. (D) If releasing pressure on the DP does not result in return of signal, the PT is released. Resumption of a distal signal under these conditions indicates that the distal foot is dependent on the PT for perfusion.

The lower-extremity Allen test (LEAT) is easy to perform and helps the reconstructive surgeon better determine the functional consequences of respective arterial selection.

METHODS: LOWER-EXTREMITY ALLEN TEST

The test is performed with the patient supine. A handheld Doppler is used to locate the first dorsal metatarsal artery in the first web space (Fig. 1A). The PT pulse or signal is identified posterior to the medial malleolus and compressed. The dorsalis pedis (DP) pulse or signal is simultaneously palpated and compressed (Fig. 1B). A persistent signal indicates collateral flow through the PA and no further analysis is required, although this situation is unusual as even a PA-dependent foot typically reconstitutes at the DP, which would be compressed. If the signal is extinguished, pressure on the DP artery is released (Fig. 1C). Return of a signal indicates adequate DP flow for perfusion of the distal foot. If releasing pressure on the DP does not result in return of signal, the PT is released (Fig. 1D). Resumption of a distal signal under these conditions indicates that the distal foot is dependent on the PT for perfusion.

CASE REPORT

A 70-year-old woman sustained a Gustilo IIIb fracture of her right lower extremity in a steam-pipe explosion. She had an unremarkable past medical history and review of systems. She was an ex-smoker. Her injury resulted in a spiral-shaped soft tissue defect with a large area of exposed bone, tendon, and muscle extending from her midlower extremity to her heel. The linear dimensions of the defect were 32 cm × 8 cm (Figs. 2 and 3). Her tibial fracture was treated by placement of an intramedullary rod at the time of her initial presentation. Serial soft tissue debridement and management with a vacuum-assisted closure (VAC) dressing followed. After demarcation and definitive debridement of her soft tissue injuries, she was scheduled for free tissue transfer for soft tissue and hardware coverage in a continued attempt at limb salvage. Given the extent and mechanism of her injury and prior orthopedic instrumentation, a preoperative angiogram was obtained.

Figure 2 Right lower extremity of 70-year-old woman following spiral-shaped soft tissue defect with a large area of exposed bone, tendon, and muscle extending from her midlower extremity to her heel. The linear dimensions of the defect were 32 cm × 8 cm.

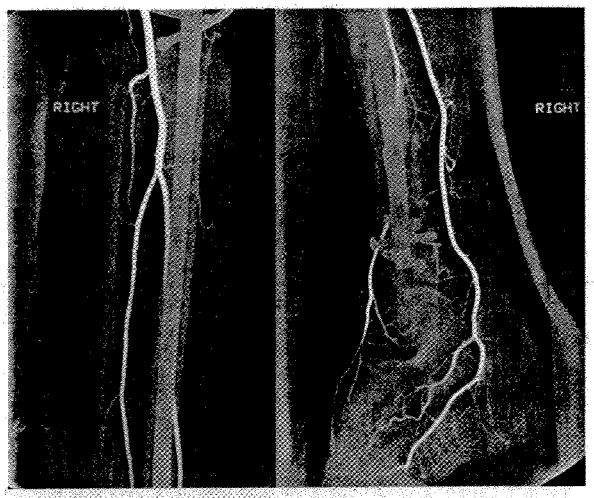

Figure 4 The angiogram revealed a variant of peroneus magnus with an atretic anterior tibial artery and apparently uninterrupted flow to the foot through both the posterior tibial artery and peroneal artery.

The angiogram revealed a variant of peroneus magnus with an atretic AT and apparently uninterrupted flow to the foot through both the PT and PA (Fig. 4). The initial plan was to transfer the rectus abdominis muscle to the lower extremity and to anastomose the deep inferior epigastric artery to the PT end-to-side or end-to-end. The patient had both palpable DP and PT pulses. A preoperative LEAT was performed with findings that suggested a PT-reliant foot. Given the discrepancy between the LEAT and the angiogram, the conclusion was made that the angiogram overemphasized the contribution of the PA system to the foot and that the foot heavily relied on the PT for perfusion. Upon dissection and exposure of the PT, the test was repeated by placing a vascular clamp across the distal segment. Again, distal perfusion was lost, confirming our digital compression examination.

These findings diminished the suitability of the PA as a recipient vessel for the free flap. The remaining options, therefore, were end-to-side anastomosis of the inferior epigastric to the deep proximal PT or use of an adequate soleal perforating branch in an end-to-end fashion. Upon exposure of the slightly more proximal PT, a soleal perforating branch was easily identified and dissected free from the muscle. It was found to be 1.6 mm in diameter with a 2.5-mm associated vein. The arterial anastomosis was performed in an end-to-end fashion with interrupted 9–0 Ethilon© (Ethicon, Inc., Somerville, NJ) sutures and the venous anastomosis was performed with a 2.5 mm anastamotic coupler (Synovis® Surgical Innovations, St. Paul, MN) rectus abdominis muscle was inset and covered with a split thickness skin graft (Fig. 5). Her postoperative course was unremarkable (Fig. 6A, B).

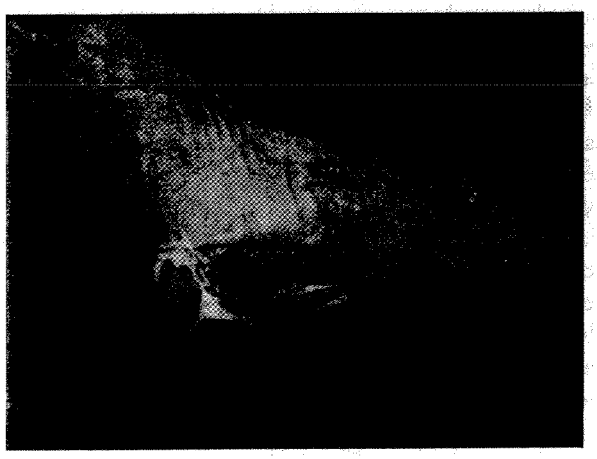

Figure 3 Right lower extremity of 70-year-old woman following spiral-shaped soft tissue defect with a large area of exposed bone, tendon, and muscle extending from her mid-lower extremity to her heel. The linear dimensions of the defect were 32 cm × 8 cm.

Figure 5 Rectus abdominis muscle was inset and covered with a split-thickness skin graft.

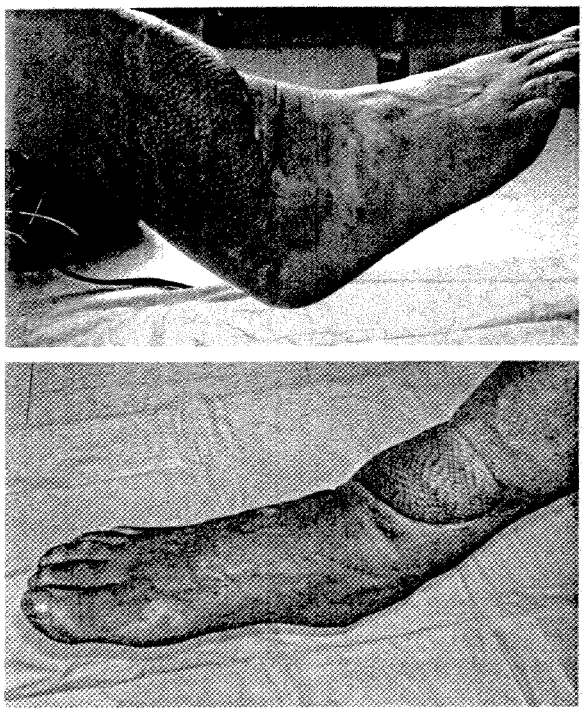

Figure 6 Reconstruction at 18 months' follow-up: (A) lateral view, (B) medial view.

DISCUSSION

Angiography is the gold standard for preoperative evaluation of lower-extremity circulation in patients with potential injury or vascular disease. In a small subset of patients, however, angiography can be misleading, and dominant circulation is not always delineated.

In the case described in this report, the LEAT was shown to be useful in demonstrating functionally relevant dominant circulation to the distal lower extremity. This test is easy to perform and should be used in adjunct to lower-extremity arterial imaging. Regardless of angiographic results, interruption of flow indicated by loss of distal signals with occlusion of the axial vessels can help reveal critical reliance of the foot on the relevant artery. If a single vessel is responsible for distal perfusion, the reconstructive surgeon must plan alternative options (perforator or retrograde flow) or an end-to-side anastomosis. Simple digital pulse examination in itself can be potentially misleading, as retrograde flow may yield palpable vessels in an otherwise healthy patient.

To understand lower-extremity vasculature, it is important to discuss embryology. Variations in normal circulation to the foot occur in 2.8 to 5.6% of the population and true peronea magna in 0.2 to 0.9%.[12,13] Initially, two vessels enter the leg, the femoral artery and the sciatic or axial artery. By the third month, the AT and PT have developed from the femoral system and the popliteal artery and PA from the axial artery. Ultimately, the axial artery disappears and the femoral artery supplies the distal circulation.[14] Therefore, the PA is the most consistently encountered artery in the lower leg, and when another vessel is congenitally missing, the PA typically provides inflow for this area.[15] True peroneus magnus refers to the variation in lower-extremity vasculature with a hypoplastic or aplastic PT and AT and a hyperplastic PA providing distal flow.

Table 1 High-Risk Patients

History of peripheral vascular disease
Diabetes mellitus
Prior vascular or orthopedic surgery on the affected extremity
Absent/diminished pedal pulses
Clinically ischemic foot
Gustilo IIIc fracture
Gustilo IIIb fracture with large zone of injury

Preoperative Algorithm

A history is obtained and a physical examination performed on patients who are referred for reconstruction of the distal lower extremity. The patient is placed into a high-risk or low-risk group for vascular insufficiency based on the presence of various historical and physical findings. These include history of peripheral vascular disease, diabetes mellitus, prior vascular or orthopedic surgery on the affected extremity, renal failure, absent distal pulses, clinically ischemic foot, Gustilo IIIc fracture, or Gustilo IIIb with a large zone of injury (Table 1). The presence of any of these findings places the patient into a high-risk group.

All high-risk patients undergo angiographic evaluation of the extremity. Once the initial planning and diagnostic workup have been completed, the LEAT can provide valuable information about clinically significant perfusion of the foot. By sequentially occluding the available arteries as determined by angiography and simultaneously assessing the Doppler signal in the first web space, it is possible to determine the relative importance of the occluded vessel to the foot perfusion. If perfusion is uninterrupted, the occluded vessel can be safely used as a recipient for the free flap in an end-to-end or end-to-side fashion. In the patient with single-vessel blood supply to the foot, options for in-flow include an end-to-side anastomosis to the single vessel or use of a secondary vessel. It should be noted that the end-to-side configuration can be technically more challenging than the end-to-end anastomosis and carries the additional risk of placing both the foot and free flap in jeopardy from technical failure. As an additional safety measure, the test is repeated intraoperatively by clamping the vessels to confirm findings prior to anastomosis. With the intraoperative clamp test, it is also possible to evaluate retrograde blood flow distal to the clamp, and the possibility of a distal end-to-end anastomosis can be considered (Fig. 7).

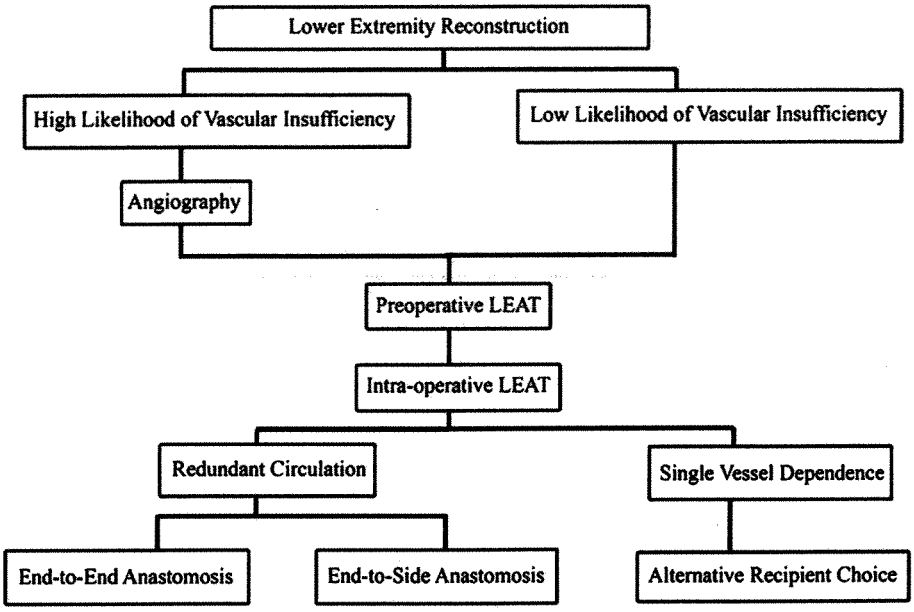

Figure 7 Algorithm for preoperative evaluation of lower-extremity soft tissue defect requiring reconstruction. LEAT, lower-extremity Allen test.

REFERENCES

1. Allen EV. Thromboangiitis obliterancs: methods of diagnosis of chronic occlusive arterial lesions distal to the wrist with illustrative cases. Am J Med Sci 1929;178:237–244
2. Cable DG, Mullany CJ, Schaff HV. The Allen test. Ann Thorac Surg 1999;67:876–877
3. Ejrup B, Fischer B, Wright IS. Clinical evaluation of blood flow to the hand. The false-positive Allen test. Circulation 1966;33:778–780
4. Bedford RF, Wollman H. Complications of percutaneous radial-artery cannulation: an objective prospective study in man. Anesthesiology 1973;38:228–236
5. Attinger CE, Evans KK, Bulan E, et al. Angiosomes of the foot and ankle and clinical implications for limb salvage: reconstruction, incisions, and revascularization. Plast Reconstr Surg 2006;117:261S–293S
6. Eiberg JP, Lundorf E, Thomsen C, et al. Peripheral vascular surgery and magnetic resonance arteriography: a review. Eur J Vasc Endovasc Surg 2001;22:396–402
7. Descotes J, Cathignol D. Classification of changes in circulatory rate in the arteries of the lower limbs. Transcutaneous measurement by Doppler effect. Nouv Presse Med 1975;4:2091–2093
8. Bone GE, Pomajzl MJ. Toe blood pressure by photoplethysmography: an index of healing in forefoot amputation. Surgery 1981;89:569–574
9. Baron HC, Hiesiger E. Significance of ankle blood pressure in the diagnosis of peripheral vascular disease. Am Surg 1979; 45:289–292
10. Nicholas GG, Myers JL, DeMuth WE Jr. The role of vascular laboratory criteria in the selection of patients for lower extremity amputation. Ann Surg 1982;195:469–473
11. Kazmers A, Koski ME, Groehn H, et al. Assessment of noninvasive lower extremity arterial testing versus pulse exam. Am Surg 1996;62:315–319
12. Lutz BS, Wei FC, Ng SH, et al. Routine donor leg angiography before vascularized free fibula transplantation is not necessary: a prospective study in 120 clinical cases. Plast Reconstr Surg 1999;103:121–127
13. Kim D, Orron DE, Skillman JJ. Surgical significance of popliteal arterial variants. A unified angiographic classification. Ann Surg 1989;210:776–781
14. Senior H. The development of the arteries of the human lower extremity. Am J Anat 1919;25:55–94
15. Lippert H, Pabst R. Arterial Variations in Man: Classification and Frequency. Verlag, Munchen: JF Bergmann; 1985