

## A New Osteotomy for Hallux Valgus:

### A Horizontally Directed "V" Displacement Osteotomy of the Metatarsal Head for Hallux Valgus and Primus Varus

DALE W. AUSTIN, D.P.M., M.D., AND EDWARD O. LEVENTEN, M.D., F.A.C.S.\*

Operations to repair bunions have been done for over a century and, according to Kelikian<sup>3</sup>, more than 100 procedures have been described in the treatment of hallux valgus—each with its own advantages and, frequently, disadvantages.

Because numerous procedures exist for correcting bunions, a surgeon must have compelling reasons to seek out another operation. Our reasons are as follows: We feel that few operations adequately solve the basic problem of hallux valgus. We believe the primary malalignment of hallux valgus is the altered shape of the articular surface of the first metatarsal head produced by a long-standing valgus drift (Fig. 1A). This altered shape can be corrected only by redirecting properly the articular surface of the first metatarsophalangeal joint. It is our opinion that failure to surgically correct this articular joint surface of the first metatarsophalangeal joint permits the recurrence of hallux valgus (Fig. 1B) except in arthroplasty or arthrodesis. In addition, the basic mechanics of normal joint motion necessitates a uniformity of joint surface contact. Any procedure that pulls the proximal phalanx straight by buckling the joint will com-

promise joint function, leading to osteoarthritis and possible hallux rigidus (Fig. 1B).

We believe that a satisfactory bunion operation should redirect the first metatarsal head to create a uniform contact at the first metatarsophalangeal joint. The hallux valgus should be fully corrected. Most of the correction of primus varus should be obtained. Rotation, or dorsiflexed attitude, of the first metatarsophalangeal joint, if present, should also be corrected, and the first metatarsal should not be significantly shortened, creating a Morton's syndrome.<sup>6</sup> This ideal operation should have adequate stability to allow early ambulation without casts. We feel we have obtained essentially all of these features in the operation to be described below.

This operation was first performed by one of us (D.W.A.) in 1962. It is a horizontally directed "V" displacement osteotomy of the head of the first metatarsal. The osteotomy is combined with a release and balancing of soft-tissue structures on both sides of the joint as described in other bunion operations.<sup>5,7</sup>

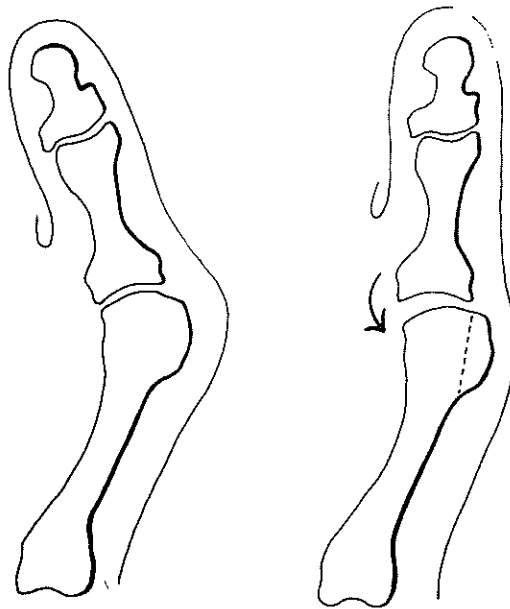
#### METHODS

The skin incision is longitudinal, about 8 cm in length, slightly curved, and located halfway between the medial exostosis and the extensor hallucis longus tendon. Care is taken to protect the sensory branch of the musculocutaneous (superficial peroneal) nerve in this area. This nerve, with its vascular bundle and extensor hallucis longus tendon, is retracted dorsally.

\* Department of Orthopedic Surgery, Kaiser Foundation Hospital, Panorama City, California.

Reprint requests to Dale W. Austin, D.P.M., M.D., 6900 Van Nuys Boulevard, Suite 9, Van Nuys, CA 91405.

Received: June 6, 1980.



FIGS. 1A and 1B. (A, left; B, right) The basic alignment during the deforming stage.

After exposing the capsular structures, a U shaped flap is created with its base attached to the proximal phalanx (Fig. 2). The head of the metatarsal is further exposed and the bony overgrowths are removed flush with the shaft. The bony cut on the medial overgrowth must be exactly vertical in preparation for the osteotomy. The rough edges are then smoothed with a rasp.

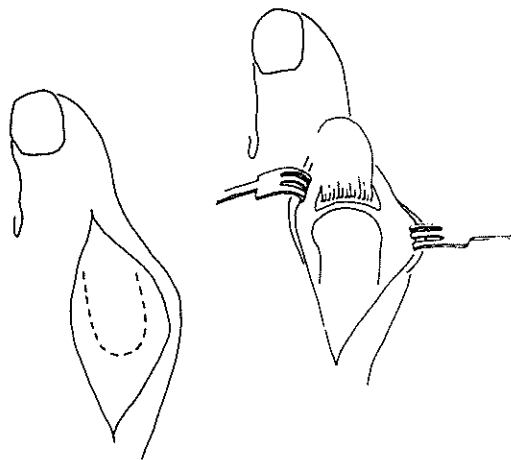


FIG. 2. The distally based capsule.

A tenotomy of the conjoined tendon is next performed through the original incision, eliminating an additional skin incision. This is done by placing the toe into traction and a varus position and reaching across the joint space to release the tendon (Fig. 3).

In preparation for the osteotomy, a 5/64-inch drill hole is centered on the tibial surface of the metatarsal head. This drill hole is placed at exactly right angles to the prepared vertical surface of the metatarsal head, and goes through both sides of the head. The hole is placed at the exact center of the imaginary circle of the head (Fig. 4), and locates the apex of the osteotomy cuts.

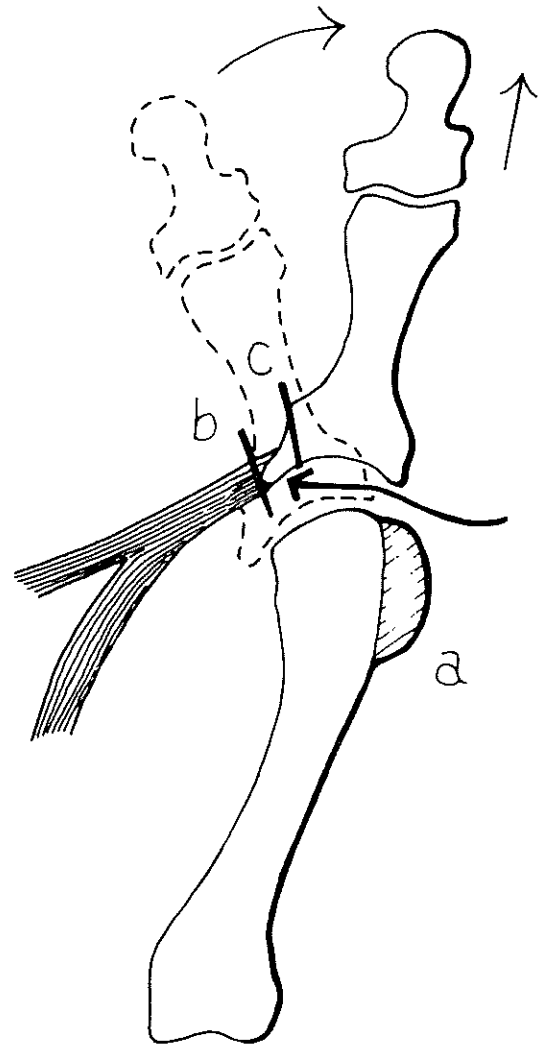


FIG. 3. Release of the adductor tendon.

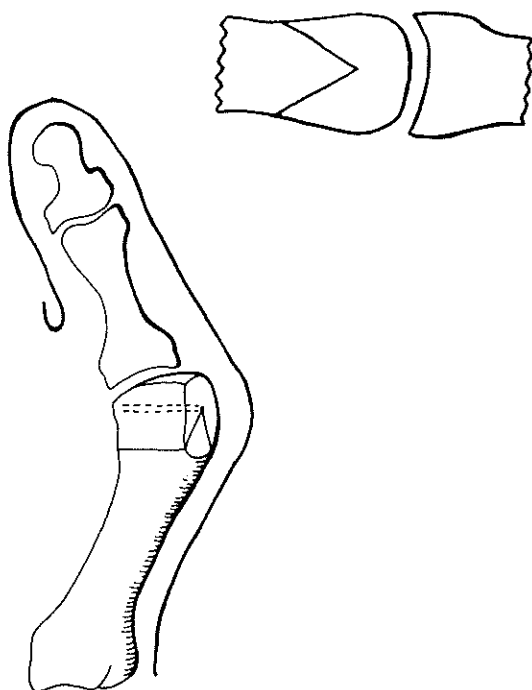


FIG. 4. The osteotomy sites.

The V osteotomy is horizontally directed, using an oscillating power saw placed on the tibial side of the head at an angle of  $60^\circ$  (Fig. 5). This angle allows the cuts to remain in the cancellous bone areas of the head, providing a broad surface of bone contact for better healing. The horizontal direction gives excellent stability. The cortices must be cut completely through to allow the head to be moved freely. The metatarsal head is now displaced laterally (fibularly) from one-fourth to one-half the width of the metatarsal, correcting some, if not all, of the primus varus (Fig. 6). At the same time, the metatarsal head is redirected

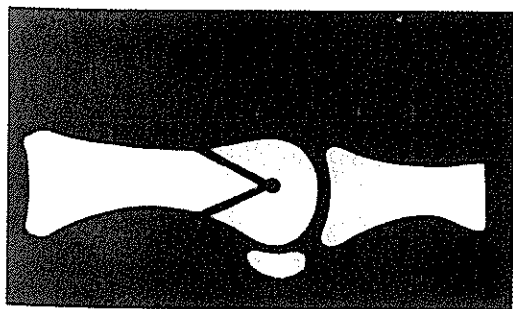


FIG. 5. The completed hallux osteotomies.

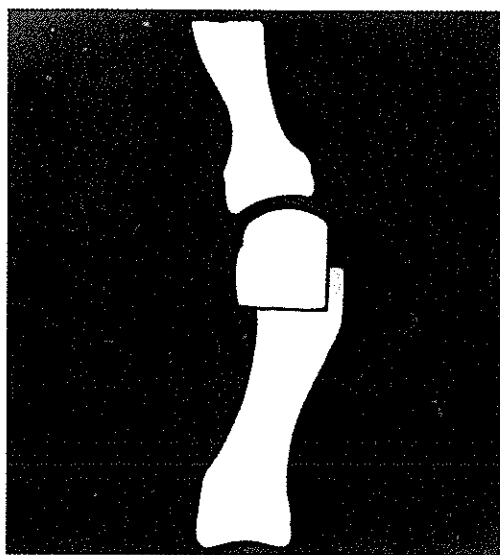


FIG. 6. Shift of the articular surface laterally.

to change the articular surface from valgus to slight varus (Fig. 7). Correction of slight degrees of angulation, rotation and/or dorsiflexion may be made at this time by slightly altering the angles of the V osteotomy; however, these adjustments are seldom necessary. The osteotomy is now impacted by the hand pressure of the surgeon (Fig. 8). The soft cancellous fragments allow significant impaction in the corrected position. Enough stability is obtained at this point that fixation is not necessary. The protruding portions of the proximal metatarsal area are then rongeuired and smoothed with a rasp (Fig. 8).

Additional drill holes are placed through the cortex of the proximal metatarsal to anchor the U-shaped capsular flap back to the bone under tension (Fig. 9). A 2-0 chromic catgut suture is used. The tie is made by the assistant while the surgeon holds the great toe in slight varus and plantar flexion, and derotation if necessary. This minimally overcorrects the hallux valgus. A series of interrupted sutures of 3-0 Dexon is now used to finish approximating the U-shaped flap to its capsular bed. Either the surgeon or the assistant should maintain the corrected attitude of the toe until this capsular closure is accomplished. Subcutaneous tissue and skin closure is done to suit the individual surgeon.

A nonadherent sterile dressing is placed over the wound and between the lesser toes. No plaster cast has been found necessary owing to the excellent stability provided by this operation.

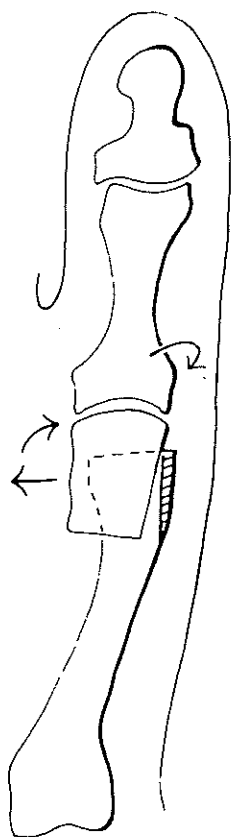


FIG. 7. Redirection of the hallux.

### POSTOPERATIVE CARE

The majority of patients have had both feet repaired at the same time. Our patients are kept at bedrest with feet elevated. They are allowed to practice dorsiflexion foot exercises during this time to decrease the incidence of thrombophlebitis and to overcome the strong tendency toward developing equinus contractures found in any foot surgery.

On the second postoperative day, the patient is allowed up in a wheelchair and may practice placing feet on the floor to further help prevent equinus attitude. A heavy sock of stockinette is added over the dressing, as a protective cover in preparation for walking.

Ambulation is usually started on the third postoperative day with the patient using a walker for balance. No postoperative wooden

shoes are employed inasmuch as this interferes with joint motion. Stockinette covers or flexible rubber-soled postoperative shoes are preferred. By the fifth or sixth postoperative day, patients are usually ambulating comfortably and are ready for discharge with crutches or no external appliances. Dressings may be left undisturbed for the postoperative first week, then redressed in the same fashion as done at the time of surgery. The skin sutures are removed in the second and third week and sterile strips and dressings may be used.

A constant effort is made to bring the lesser toes toward the great toe and close the gap created by correction of the hallux valgus. Three weeks postoperation, skin sutures are removed and all dressings are discontinued. The patient is placed in round-toed blucher-style tennis shoes, and these are changed to round-toed leather oxford shoes as soon as swelling permits. Since many patients with hallux valgus have associated medial foot imbalance, a foot-balancer ap-

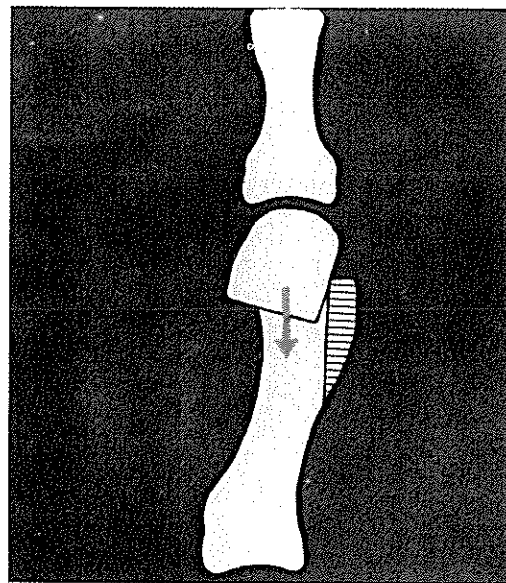


FIG. 8. Compression of the head on the metatarsal neck.

pliance employing a medial heel wedge with a fifth metatarsal wedge can be used.

After hallux valgus surgery, the feet are in a plastic state for about two months, and extra care is necessary to assure they will continue to heal in the correct alignment.

### INDICATIONS

Candidates for our operation are persons with foot symptoms in addition to mild-to-moderate hallux valgus and primus varus. We do not usually perform this operation on patients with clinical or roentgenographic evidence of joint cartilage destruction. Since the osteotomy site is not near a growth plate, younger patients may also have this operation. The youngest patient we have had was only 8 years old.

Because aging is a physiologic and not merely a chronologic process, we will operate on older persons if they show evidence of healthy joint cartilage. Our oldest patient was 76 years old. As with any elective foot surgery, systemic or circulatory contraindications must be considered. Patients with articular cartilage destruction from arthritic changes will usually do better with arthroplasty techniques possibly employing joint implants.<sup>8</sup>

### DISCUSSION

One of us (D.W.A.) initiated this procedure in 1962 and operated on 25 patients; subsequently we collaborated and operated on an additional 300 patients within a three-year period. Since 1969 we have increased our series together, and it now includes over 1,200 cases.<sup>2,4</sup>

In our initial 300 operations, there was a 10% recurrence rate of hallux valgus and a few cases of hallux varus. These problems have been traced back either to inadequate correction of the bony elements or to inadequate soft-tissue balancing. Only 12 of these cases required re-operation and following realignment had no further problems; 5% of this group have had some discomfort with

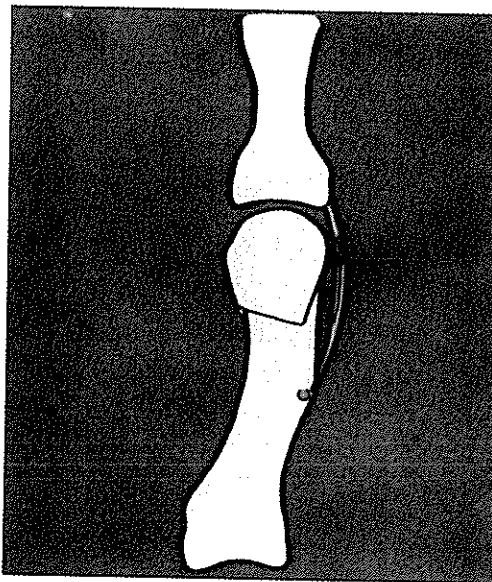


FIG. 9. Reattachment of the medial capsule to the bone.

joint motion and/or slight limitation of joint motion. Less than half required arthroplasty revision.

In this series, there was no significant shortening of the first metatarsal. In 100 cases, selected randomly for analysis, only an average of 1/4-inch shortening was found. This slight amount results in no significant transfer of weight to the second metatarsal head with the resulting problems of Morton's syndrome.

We have had no complications of thrombophlebitis, nonunion of osteotomy, or recognized avascular necrosis of the metatarsal head. No significant wound infections occurred, although 42 patients in this series of 1,200 had a superficial and transient infection which cleared up promptly. Disability after this operation has been so minimal that most patients can return to full activity in six to eight weeks.

### SUMMARY

A new operation for hallux valgus consists of a horizontally directed "V" displacement

osteotomy done in the head of the first metatarsal. This procedure corrects most of the primus varus, the valgus tilt of the articular surface of the first metatarsal and, if present, the axial rotation of the great toe. The osteotomy is combined with a release and balancing of soft-tissue structures on both sides of the joint. No casting and usually no internal fixation is necessary. Ambulation is generally recommended on the third postoperative day. The operative techniques, indications for surgery, clinical material, and postoperative care are discussed. The operation, when done correctly, does not result in recurrence of the deformity. Significant complications are rare.

## REFERENCES

1. Austin, D. W.: Practical aspects of misbalance. *Clin. J. Chir. Podiatry Pediatr. Surg.* 11:7:223, 1940.
2. Austin, D. W., and Leventen, E. O.: Scientific exhibit of V-osteotomy of the first metatarsal head. AAOS Chicago, 1968.
3. Kelikian, H.: *Hallux Valgus, Allied Deformities of the Forefoot and Metatarsalgia*. Philadelphia, W. B. Saunders Co. 1965, p. 163.
4. Leventen, E. O., and Austin, D. W.: Film, "Bunion Surgery, A New Approach." AAOS, San Francisco, 1975.
5. McBride, E. E.: A conservative operation for bunion. *J. Bone Joint Surg.* 10:835, 1928.
6. Morton, D. J.: *The Human Foot*. New York, Columbia University Press, 1935.
7. Silver, D.: The operative treatment of hallux valgus. *J. Bone Joint Surg.* 5:225, 1923.
8. Swanson, A. B.: Implant arthroplasty in the foot (Lecture). Film, "The Adolescent and Adult Foot and Ankle" AAOS Cincinnati, 1975.