

## CASE STUDY

### PATIENT:

69 year-old, male.

### WOUND HISTORY:

- 9 month old wounds
- Wounds caused due to trauma in March 2019
- MRSA infection diagnosed in June 2019 and treated with Doxycycline
- Experienced persistent and sharp pain, especially when walking, used pain killers on a regular basis

### PAST MEDICAL HISTORY:

Diabetic Mellitus Type 2

### PAST TREATMENTS:

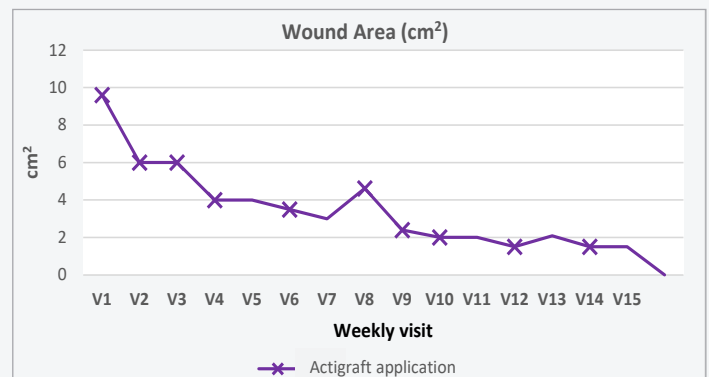
Ultra-MIST treatment – thrice weekly and topical European Wound Gel, Allicin

### OFFLOADING:

Boot

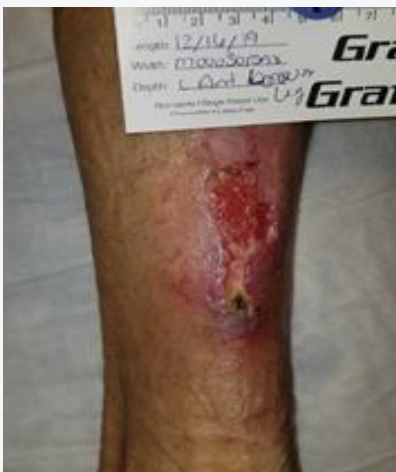## LOWER LEG

- 100% WOUND REDUCTION
- TOTAL HEALING IN 16 WEEKS
- 10 ACTIGRAFT APPLICATIONS

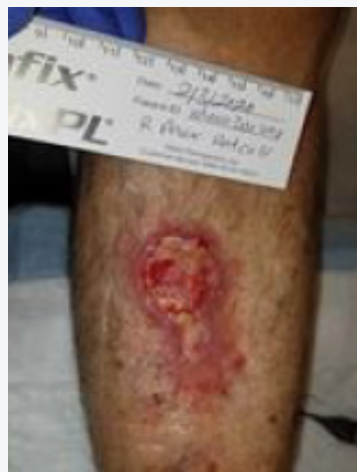

### ACTIGRAFT TREATMENT PROGRESSION:

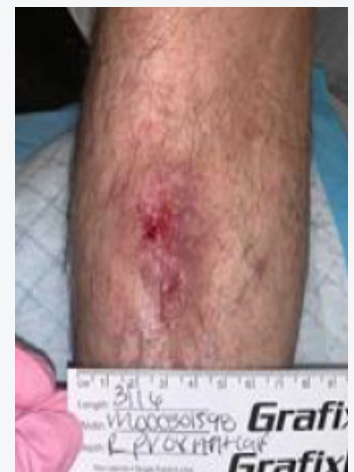Day 0



Day 49

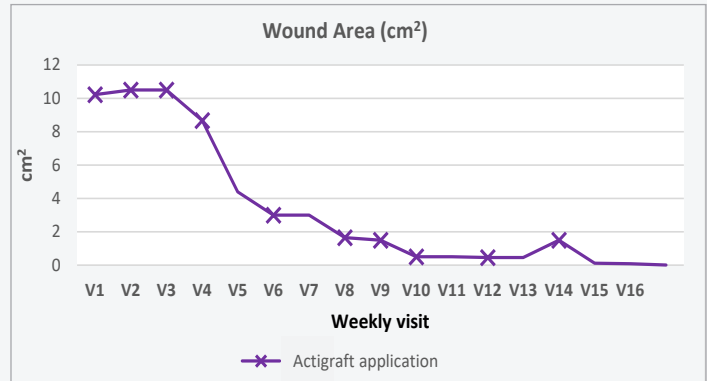


Day 91



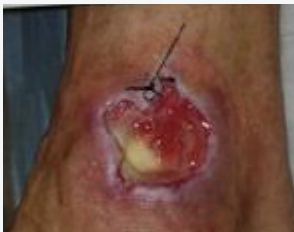## ANKLE

- 100% WOUND REDUCTION
- TOTAL HEALING IN 19 WEEKS
- 10 ACTIGRAFT APPLICATIONS

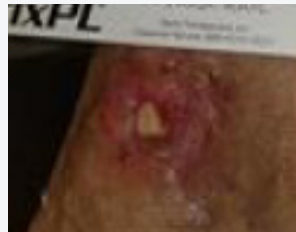

### ACTIGRAFT TREATMENT PROGRESSION:

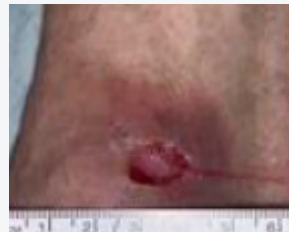Day 0



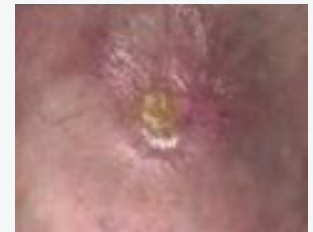Day 49



Day 91

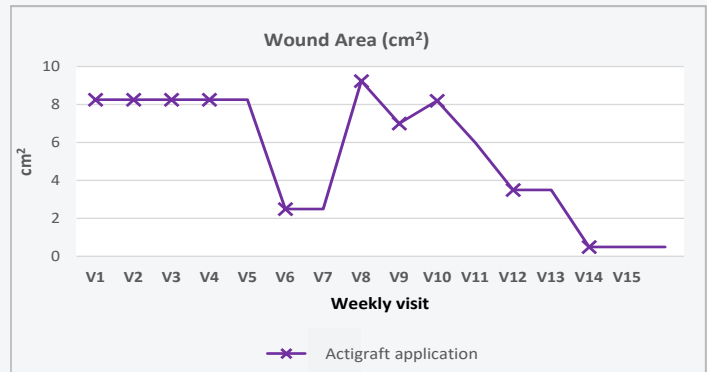


Day 127



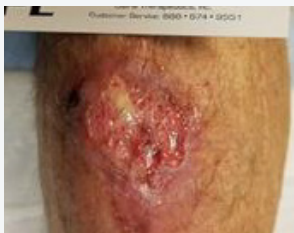## CALF

- 100% WOUND REDUCTION
- TOTAL HEALING IN 16 WEEKS
- 10 ACTIGRAFT APPLICATIONS

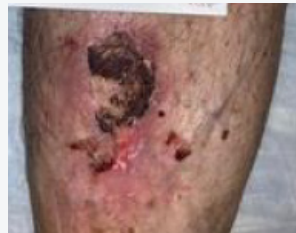

### ACTIGRAFT TREATMENT PROGRESSION:

Day 0



Day 64



Day 91

